

Segmental agenesis of the uterine body, cervix and vagina in a bitch

CHUL HO PARK¹, CHANG HO SON^{2*}

¹Veterinary Teaching Hospital, Chonnam National University, Gwangju, Republic of Korea

²College of Veterinary Medicine, Chonnam National University, Gwangju, Republic of Korea

*Corresponding author: chson@jnu.ac.kr

Citation: Park CH, Son CH (2019): Segmental agenesis of the uterine body, cervix and vagina in a bitch. *Veterinari Medicina* 64, 134–137.

Abstract: This report describes a case of congenital segmental agenesis of the uterine body, cervix and vagina in a bitch. A five-year-old, Pomeranian bitch was presented with anorexia, abdominal distension and absence of the oestrus vulvar discharge. Complementary examinations were performed and ultrasonography revealed marked distention of the uterine horns with fluid-filled thin wall and defects in the uterine-vaginal segment. During surgery, closer inspection of the reproductive tract showed segmental agenesis of the uterine body, cervix and cranial part of vagina. The dog recovered uneventfully and six months later there were no further specific problems.

Keywords: Müllerian duct; congenital defect; uterine-vaginal segment

Non-development or non-fusion of Müllerian ducts may result in a variety of anomalies ranging from complete agenesis to duplication of female reproductive organs (Moore and Persaud 2008). These congenital reproductive anomalies are commonly reported in sows and cows (Kennedy and Miller 1993). The prevalence of these anomalies ranges from 0.02% to 0.05% in the canine popula-

tion (McIntyre et al. 2010). Segmental aplasia of the uterine horn (partial or complete) is relatively common in dogs (Schulman and Bolton 1997; McIntyre et al. 2010; Vince et al. 2011). However, few reports have been published about segmental aplasia of the uterine body in dogs (Oh et al. 2005; McIntyre et al. 2010) and, to the best of our knowledge, only one case of cervical aplasia has been reported in dogs

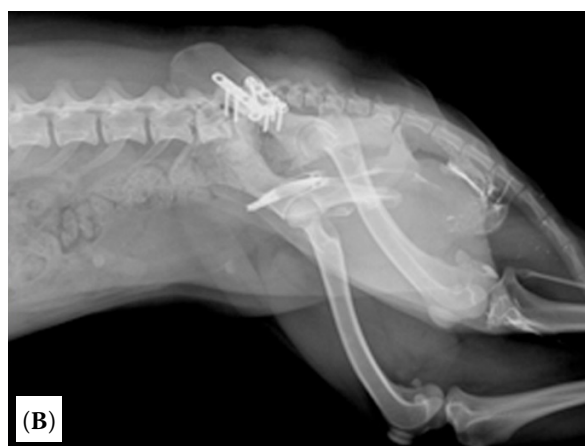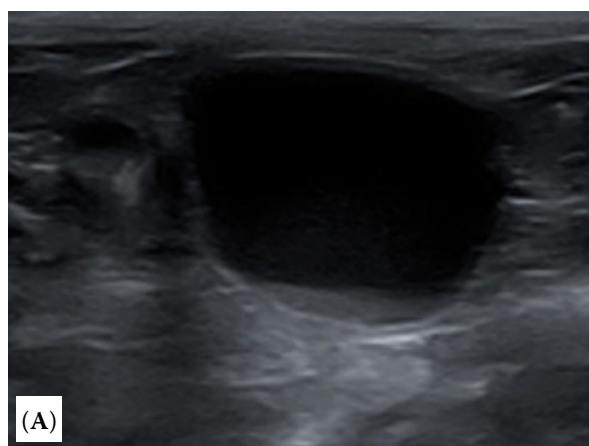


Figure 1. (A) Ultrasound image showing distended uterine horn with fluid-filled thin wall. (B) Vaginal contrast radiography showing the blind-ending cranial part of the vagina

<https://doi.org/10.17221/139/2018-VETMED>

by McEntee (1990). To our knowledge, this is the first described case of segmental agenesis of the uterine body, cervix and vagina in a bitch.

Case description

A 5.6-kg, five-year-old Pomeranian bitch was presented with anorexia and abdominal distension. The owner reported that the bitch had a history of surgery for treatment of a pelvic bone fracture two years previously, and she did not have serosanguineous vaginal discharge at oestrus. On physical examination, the bitch was bright and alert. Complete blood count, serum biochemistry and blood gas analysis did not show any significant findings. On abdominal ultrasonographic examination, the left and right uterine horns were distended to a maximum of about 3 cm in diameter with fluid-filled thin wall (Figure 1A). However, the uterine cervix could not be observed in the dorsal part of the urinary bladder. Vaginal contrast radiography showed that the vagina was blocked at the cranial two-thirds of the vulva (Figure 1B). On the basis of these findings, the tentative diagnosis was congenital anomalies of the reproductive tract.

Therefore, an ovariohysterectomy was performed to remove the ovaries and uterus.

At surgery, closer inspection of the reproductive tract showed enlarged bilateral uterine horns with fluid and the uterine body, cervix and cranial part of the vagina appeared to be absent, with the uterine horns and cranial part of the vagina consisting of a blind-ending connected by broad liga-

ment (Figure 2). Only blood vessels were observed within this portion of the broad ligament. Upon gross examination, the removed bilateral uterine horns were equivalently distended with mucoid, greyish-coloured fluid and were communicating between the uterine horns ending blindly at the junction (Figure 3). Histopathologically, the uterine horns showed cystic endometrial hyperplasia with multiple *corpora lutea* on both ovaries (Figure 4). In addition, the uterine mucoid fluid was found to be sterile in microbiological analysis.

DISCUSSION

During the embryonic stage, the caudal regions of Müllerian ducts are initially separated by a septum resulting in fusion and the formation of a single Y-shaped tubular structure called the uterovaginal primordium. The uterovaginal primordium becomes the uterine body, cervix and the cranial third of the vagina (Moore and Persaud 2008). During this process, developmental defects of the Müllerian duct system may cause diverse instances of agenesis or aplasia of the female reproductive tract. Segmental aplasia of the uterus may involve complete (uterus unicornis) or incomplete (uni or bilateral) segmental uterine horn aplasia, when segments of Müllerian ducts fail to develop; segmental aplasia of the body or the cervix, or longitudinal septation of the body (uterus didelphus), when caudal parts of Müllerian ducts fail to fuse appropriately and develop a single lumen (Jones et al. 1996; Vince et al. 2011).

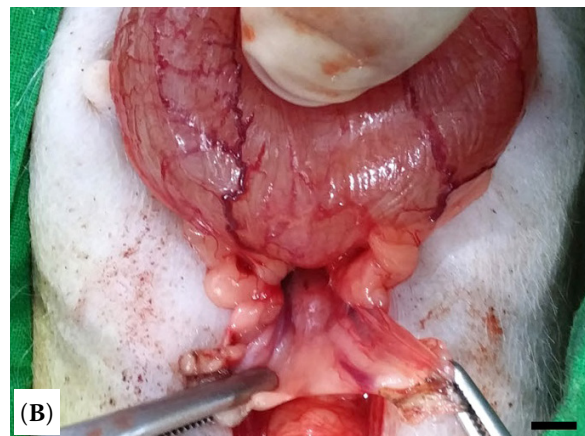
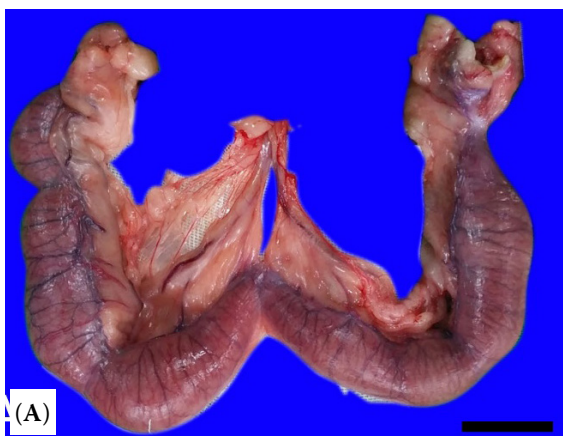

Figure 2. (A) Surgical specimen, after excision, uterine body and cervix, cranial part of the vagina appeared to be absent. The uterine horns and caudal part of the vagina consisted of a blind-ending connected by broad ligament. Bar = 2 cm. (B) Caudal part of the vagina was found to have a clogged end. Bar = 2 cm

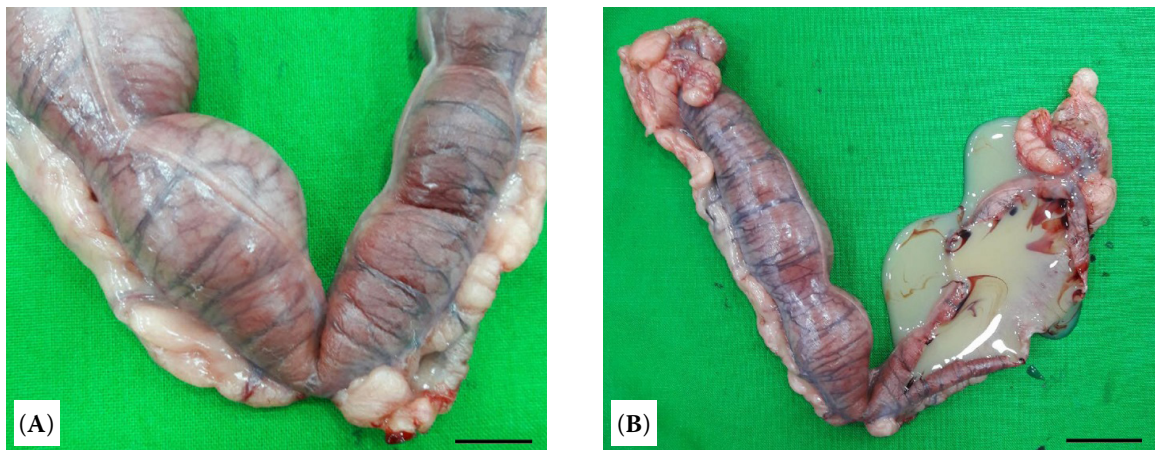


Figure 3. (A) Closer inspection of the surgical specimen showing the uterus after ovariectomy. The uterine horns showing equivalent distention and fluid accumulation due to defects of the uterine body and cervix. Bar = 1 cm. (B) Section of the uterus with mucoid fluid spilling out. Bar = 2 cm

Congenital abnormality of the uterine body or the cervix is very rare compared to segmental aplasia of the uterine horn in dogs (McEntee 1990; Oh et al. 2005; McIntyre et al. 2010). In previous reports, animals with congenital abnormalities such as segmental aplasia of the uterine body or the cervix were found incidentally during the surgical procedure, and both uterine horns were found to be equivalently distended with fluid accumulation. Undeveloped segments of the uterine body were usually detected as cord-like remnants (McEntee 1990; Oh et al. 2005; McIntyre et al. 2010). In this case, the bilateral uterine horns were equivalently distended and com-

municating as reported previously. In contrast, the uterine body, cervix and cranial part of the vagina were not detected by ultrasonography and gross examination, and, also, no cord-like remnant tissue was observed during surgery.

In the case of congenital defects of the uterine body or the cervix, the main clinical signs are the absence of vaginal discharge at oestrus and infertility. Other symptoms including abdominal distention, bilateral uterine distention and mucometra have been observed during diagnosis and treatment (McEntee 1990; Oh et al. 2005; McIntyre et al. 2010; Batista-Arteaga et al. 2012). The clinical signs in the current case were the lack of vaginal discharge, mucometra and uterine distention similar to previous studies. The clinical signs confirmed in this case were caused by accumulation of fluids in the uterine horns, which was in turn, induced by mechanical occlusion due to lack of communication between uterine horns and the vagina as described by Batista-Arteaga et al. (2012).

The most important aspect for diagnosis of segmental aplasia of the uterine body or cervix is the confirmation of the aforementioned clinical symptoms (Oh et al. 2005; McIntyre et al. 2010; Batista-Arteaga et al. 2012). In this case, the dog was suspected of having uterine cervix or vaginal problems with absence of vaginal discharge at oestrus and ultrasonography and vaginography were used to diagnose defects in the uterine-vaginal segment.

In conclusion, this is the first described case of agenesis of the uterine body, cervix and cranial va-

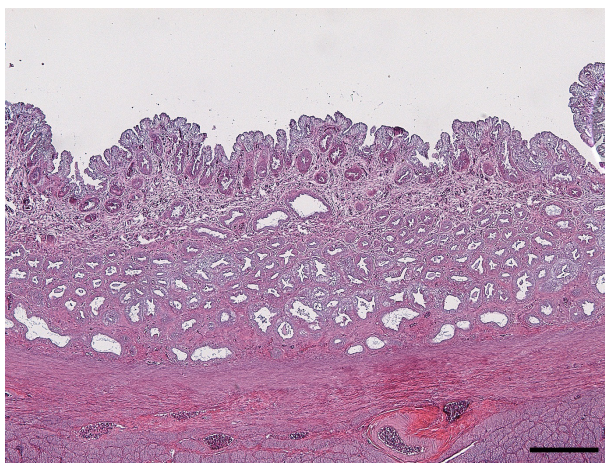


Figure 4. The perimetrium, myometrium and endometrium of the uterus have normal architectures. The uterus showed severe diffuse cystic endometrial hyperplasia characterised by multiple cystic formations in the endometrium. Bar = 200 µm

<https://doi.org/10.17221/139/2018-VETMED>

gina in a bitch. Agenesis of the uterine-vaginal segment is a rare Müllerian duct anomaly in bitches. The important symptoms for diagnosis of the agenesis of the uterine-vaginal segment are the typical clinical signs such as absence of the oestrus vulvar discharge and uterine distention with mucometra. Furthermore, ultrasound is a good and easy diagnostic option for this condition.

REFERENCES

- Batista-Arteaga M, Santana M, Espinosa-de-los-Monteros A, Deniz S, Alamo D, Herraiz P (2012): Exuberant mucometra associated with atresia of the cervix in a queen. *Reproduction in Domestic Animals* 47, e71–e74.
- Jones TC, Hunt RD, King NW (eds) (1996): *Veterinary Pathology*. 6th edn. Williams and Wilkins, Philadelphia. 1149–1221.
- Kennedy PC, Miller RB (1993): The female genital system. In: Jubb KVF, Kennedy PC, Palmer N (eds): *Pathology of Domestic Animals*. 4th edn. Academic Press, San Diego. 349–469.
- McEntee K (1990): *Reproductive Pathology of Domestic Mammals*. 1st edn. Academic Press, San Diego. 118–124.
- McIntyre RL, Levy JK, Roberts JF, Reep RL (2010): Developmental uterine anomalies in cats and dogs undergoing elective ovariohysterectomy. *Journal of the American Veterinary Medical Association* 237, 542–546.
- Moore KL, Persaud TV (eds) (2008): *The Developing Human: Clinically Oriented Embryology*. 8th edn. Saunders & Elsevier, Philadelphia. 243–269.
- Oh KS, Son CH, Kim BS, Hwang SS, Kim YJ, Park SJ, Jeong JH, Jeong C, Park SH, Cho KO (2005): Segmental aplasia of uterine body in an adult mixed breed dog. *Journal of Veterinary Diagnostic Investigation* 17, 490–492.
- Schulman ML, Bolton LA (1997): Uterine horn aplasia with complications in two mixed-breed bitches. *Journal of the South African Veterinary Association* 68, 150–153.
- Vince S, Zevrnja B, Beck A, Folnozic I, Geres D, Samardzija M, Grizelj J, Dobranic T (2011): Unilateral segmental aplasia of the uterine horn in a gravid bitch – a case report. *Veterinarski arhiv* 81, 691–698.

Received: September 30, 2018

Accepted after corrections: January 15, 2019