

## The expression of sialylated molecules in parafollicular-cell hyperplasia of the canine thyroid gland

L. VAJNER<sup>1</sup>, V. VORTEL<sup>†</sup>, A. BREJCHA<sup>2</sup>

<sup>1</sup>*Institute of Histology and Embryology, 2nd Medical Faculty, Charles University, Prague, Czech Republic*

<sup>2</sup>*Department of Pathology, BioTest, Rosice nad Labem, Czech Republic*

**ABSTRACT:** During the 18-year period (1974–1991), the lymphocytic thyroiditis with the finding of serum autoantibodies against thyroglobulin was diagnosed in 180 Beagle dogs (92 males and 88 females). In 107 of them (56 males and 51 females), hyperplasia of parafollicular cells was concurrently encountered. In further 11 cases (3 males and 8 females), solid cellular structures were found in the thyroid parenchyma, in 4 females combined with unilocular or multilocular lymphoepithelial cysts. Grimelius stain revealed the presence of parafollicular cells even at the periphery of cellular nests. Using the lectin histochemistry with *Maackia amurensis* agglutinin (MAA), *Sambucus nigra* agglutinin (SNA) and *Tritrachomonas mobilensis* lectin (TML), the presence of sialylated molecules was demonstrated in the cell membranes and perinuclear cytoplasmic regions of parafollicular cells that formed hyperplastic nodules or were interspersed in “solid cell nests”.

**Keywords:** Beagle dog; C-cell hyperplasia; solid cell nests; thyroid; sialylation; lectin histochemistry

### INTRODUCTION

The C-cell hyperplasia in the context of Hashimoto's thyroiditis is a common phenomenon according to e.g. Libbey *et al.* (1989) and LiVolsi (1990). Certain preponderance of C-cell hyperplasia was indicated in findings of Scheuba *et al.* (2000) in hyperthyroid human patients suffering from Graves disease. Authors did not reveal any dependence of this finding on the age or sex. On the other hand, Martin-Lacave *et al.* (1999) revealed the positive C-cell hyperplasia-dependence on both age and sex in rats. In addition, Vollenweider and Hedinger (1988) distinguished “solid cell nests” (SCN) deriving them from the 4th branchial pouch and classified their three subtypes. In 80%, they described small round groups of elongated cells with non-voluminous cytoplasm, organised in solid epidermoid clusters. Solid nests composed of large polygonal cells were encountered in 55% of cases; in 30%, cystic structures were found in addition to these nests. The picture of SCN was found in 51% of Hashimoto's thyroiditis in humans. No cells positive for thyroglobulin or calcitonin were revealed. Parafollicular cells were often found located at the periphery of SCN or even interspersed within SCN. Most of SCN were surrounded by lymphocytes. LiVolsi (1990) presented the frequency of SCN incidence within healthy human thyroid glands as being 14 to 28% (including a lymphocytic lining). Ozaki *et al.* (1991) revealed similar findings. Beckner *et al.* (1990) did not recommend using the term „SCN“ because up to 55% of newborn cases

contained cystic structures, and supposed the epithet “ultimobranchial body (UBB) remnants”. According to immunocytochemical features, Cameselle-Teijeiro *et al.* (1994a) classified the main cells (non-committed ultimobranchial cells) and C-cells proper within SNC, they also described mixed thyroidal follicles in which lining epidermoid cells were present. Cameselle-Teijeiro *et al.* (1994b) as well as Michal *et al.* (1996) also emphasised the enormous developmental potential of such cellular lines and related it to histogenesis of thyroid tumours. Recently, Watanabe *et al.* (1995) and Ryška *et al.* (1997) described intrathyroidal lymphoepithelial cysts in detail, which they derived from UBBs. Leblanc *et al.* (1990) analysed the SCN occurrence in dogs. They evaluated the thyroidal C-cell complexes in beagles and found them containing follicular thyroglobulin-positive cells, calcitonin- and neurone specific enolase-positive C-cells, somatostatin-positive stellate or cuboidal cells, and cells without any above-mentioned positive reaction. Lesions were featured with voluminous cellular regions both inside the thyroid parenchyma and at its periphery. Authors compared these C-cell complexes with SCN in humans and supposed them to be possible precursors of the mixed thyroidal carcinoma or medullar thyroidal carcinoma, described in dogs by Patnaik and Lieberman (1991) and in humans by Martin *et al.* (2000).

Tumours of Hürthle cells in the thyroid gland were described by Chetty (1990) who found them containing thyroglobulin and vimentin. He supposed the origin of these

cells to be unclear. Tang *et al.* (1994) dealt with ultrastructural and immunocytochemical characteristics of the canine thyroidal oncocyoma.

Glycoconjugates expressed on cell membranes of differentiating or transforming cells were supposed to play an important role in their recognition, interactions, and functional specialisation. Duprat *et al.* (1985) emphasized the advantage of lectin histochemistry in visualisation of such molecules. Nishiyama *et al.* (1996) described the expression of polysialylated contact molecules on the cell membrane in parafollicular cells especially in the period of their migration from the ultimobranchial bodies into the thyroid parenchyma. The role of the time-specific sialylation of glycoconjugates, i.e. the dynamical control during development, migration or regeneration of cell populations was stressed by Phillips *et al.* (1997). Ding *et al.* (1997) supposed the expression of the surface sialylated molecules as a sign of the higher proliferative activity and malignancy.

Therefore we decided to find out whether sialylated molecules were expressed in the cytoplasm or on the surface of parafollicular cells in their hyperplasia that had been revealed as a concurrent finding in spontaneous autoimmune lymphocytic thyroiditis (LT), not depending on its degree, in a Beagle dog breeding colony (Vajner, 1997; Vajner *et al.*, 1997).

## MATERIAL AND METHODS

Animals were autopsied and histologically examined at the Department of Pathology of the Research Institute for Pharmacy and Biochemistry at Rosice nad Labem. They served either as experimental animals for various drug safety-evaluating studies or came as old animals from the breeding colony. Investigated dogs belonged to the 180-member group (92 males and 88 females) in which we found the spontaneous lymphocytic thyroiditis (Vajner, 1997; Vajner *et al.*, 1997).

Formalin-fixed thyroid glands were routinely paraffin-embedded and cut at 4–5  $\mu\text{m}$ . Slides were stained with haematoxylin-erythrosin (HE), with the combined Alcian Blue (pH 2.5)-PAS-method (AB-PAS), and with the method for argyrophil cells after Grimelius (Grimelius, 1968).

Sata's modification (Sata *et al.*, 1990) of lectin histochemistry with digoxigenin-labelled *Maackia amurensis* agglutinin (MAA) and *Sambucus nigra* agglutinin (SNA) (Boehringer Mannheim Biochemica, Mannheim, Germany) was performed as well. Reaction of Tritrichomonas mobilensis lectin (TML) (Calbiochem, La Jolla, USA) was visualised using primary anti-TML monoclonal antibody (Calbiochem, La Jolla, USA), secondary rabbit antibody against the whole molecule of mouse IgG labelled with alkaline phosphatase (Sigma-Aldrich Chemie, Deisenhofen, Germany), and the X-phosphate-nitroblue tetrazolium system (Vajner *et al.*, 2000). As the alternative method,

biotinylated TML (a gift of Dr. Babál) was used. Its binding was visualised using streptavidine – horseradish peroxidase – diaminobenzidine – hydrogen peroxide system.

## RESULTS

Hyperplasia of the parafollicular cells was encountered in 107 cases (59.4%), in 56 males (60.9%) and 51 females (58.0%). The lesion involved the thyroid parenchyma in various range, from isolated foci or nodules (Figure 1) to the diffuse involvement filling almost the whole section of a lobe. Signs of the expansive growth or capsule formation as well as the invasive affection of follicles were never seen. Hyperplastic areas were composed of cells with pale eosinophilic abundant cytoplasm and rather eccentrically located round nuclei. Both PAS-reaction and AB-staining were negative in these cells. Granules contained in their cytoplasm were impregnated after Grimelius (Figure 2). Their cell membranes and/or cytoplasmic perinuclear compartments reacted positively to lectins MAA and TML (Figure 3). Reaction of SNA was not identified. C-cells in non-hyperplastic areas did not reveal any reaction to lectins used.

In further 11 cases (6.1%), 3 males (3.3%) and 8 females (9.1%), solid cell nests were encountered in the thyroid parenchyma. These nests were composed of compactly arranged, large round pale eosinophilic elements with round voluminous nuclei. Such cells did not react positively to any of the above-mentioned methods. On the contrary, individual elements reacting identically to parafollicular cells of hyperplastic areas were found rarely interspersed within solid cell nests or at their periphery (Figures 4, 5, and 6). In 4 females of this group, solid cell nests neighboured solitary or multilocular cysts (Figure 7), lined with squamous stratified non-keratinized epithelium, very often revealing mitoses in its basal layer. Somewhere, this epithelium transitioned in the simple columnar ciliated epithelium with goblet cells. Mucous granules of goblet cells revealed the positive reaction to both AB-PAS method and the lectins used. Non-conspicuous marginal lymphocytic infiltration and/or slightly increased number of fibroblasts were usually found surrounding the structures. Grimelius stain identified rare parafollicular cells at the periphery of these cysts.

## DISCUSSION

Parafollicular cell-hyperplasia was the finding encountered in dogs concurrently with lymphocytic thyroiditis independent on its degree. Mawdesley-Thomas and Jolly (1967), however, suggested its dependence on the higher degrees of the thyroid involvement. Libbey *et al.* (1989) and LiVolsi (1990) held parafollicular cell-hyperplasia in humans for a common phenomenon as well. Our findings

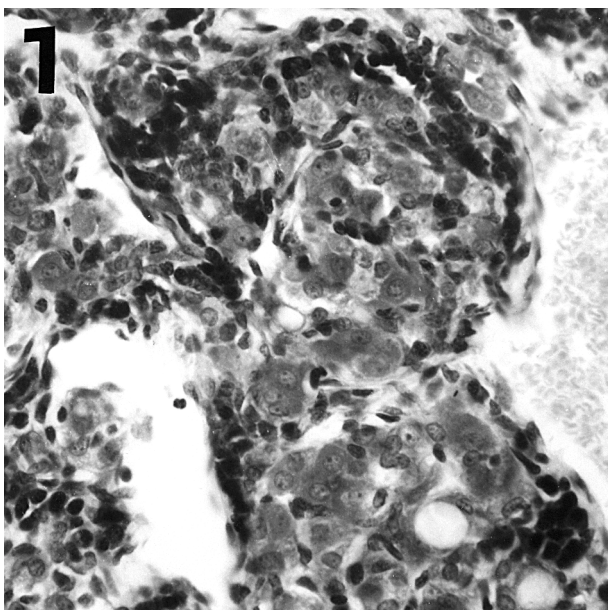


Figure 1. C-cell complex. Cresyl Fast Violet. Enlarged 40 times

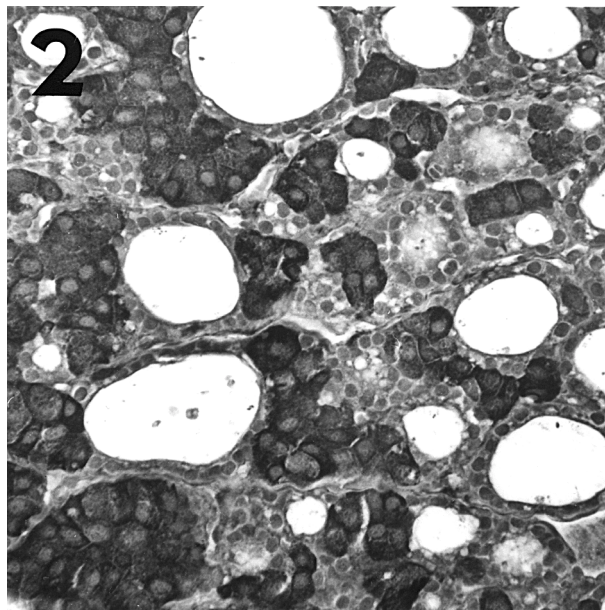


Figure 2. C-cell complex. Grimelius stain. Enlarged 40 times

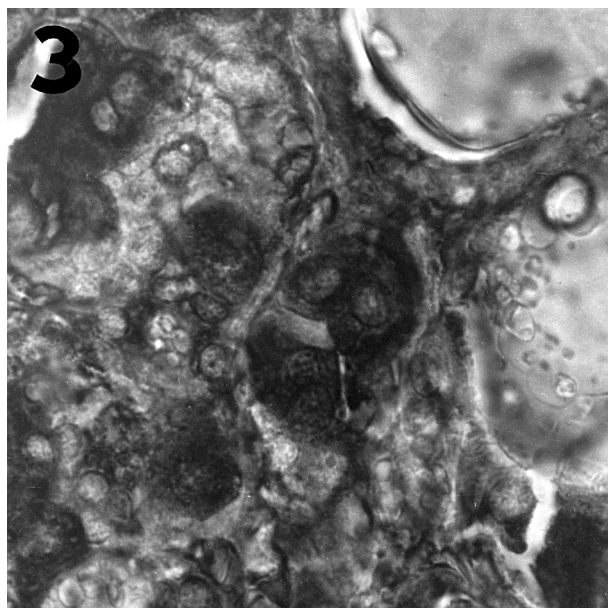


Figure 3. C-cell complex. Biotinylated *Tritrichomonas mobilensis* lectin-reaction. Enlarged 100 times

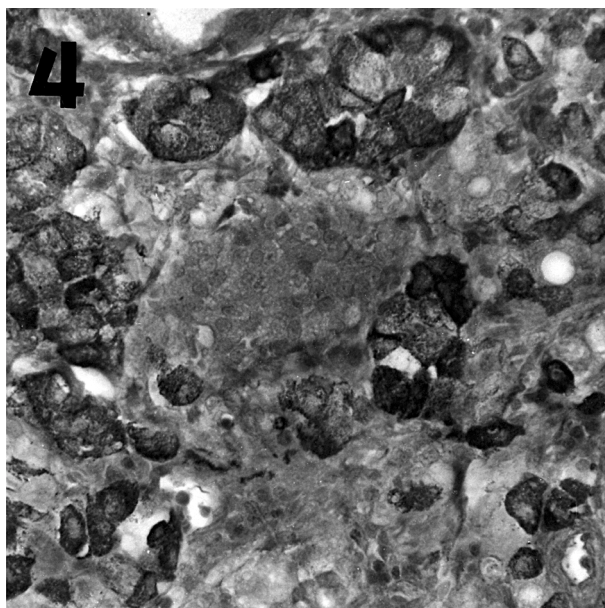


Figure 4. Solid cell nest. Grimelius stain. Enlarged 40 times

of this lesion, both previous (Vajner *et al.*, 1997) and recent, in almost 60% of animals suffering from lymphocytic thyroiditis supported this opinion. The dependence on sex seemed to be improbable in accordance to findings in humans (Scheuba *et al.*, 2000).

Solid cell nests might be also held as a common phenomenon, sex-independent as well; the picture was identical in both humans and dogs (Vollenweider and Hedinger, 1988; LiVolsi, 1990; Beckner *et al.*, 1990; Leblanc *et al.*, 1990; Ozaki *et al.*, 1991). On the contrary to findings in humans, the incidence frequency was found lower in our

study. The composition of lesions matched very well with those described by Leblanc *et al.* (1990) and Cameselle-Teijeiro *et al.* (1994a). Cystic lesions were found identical with findings of Watanabe *et al.* (1995) and Ryška *et al.* (1997).

Dogs could thus serve as a suitable model for such lesions in humans.

According to findings of Duprat *et al.* (1985), Nishiyama *et al.* (1996), Phillips *et al.* (1997), and Ding *et al.* (1997), the expression of the sialylated molecules in the para-fol-



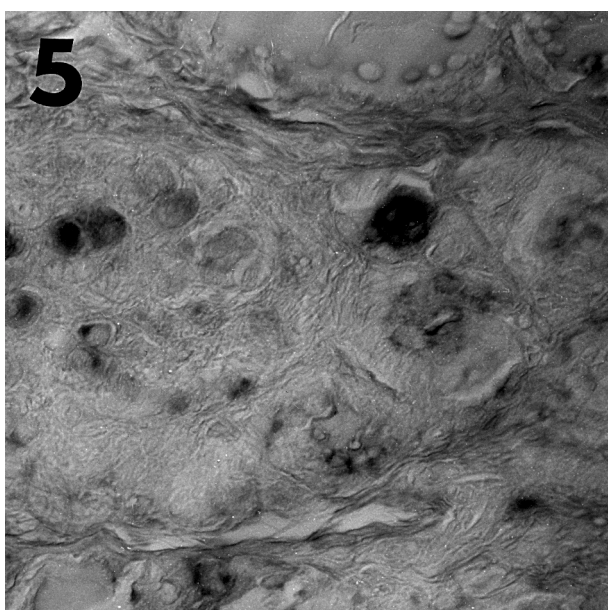


Figure 5. Solid cell nest. *Maackia amurensis* agglutinin-reaction. Enlarged 40 times

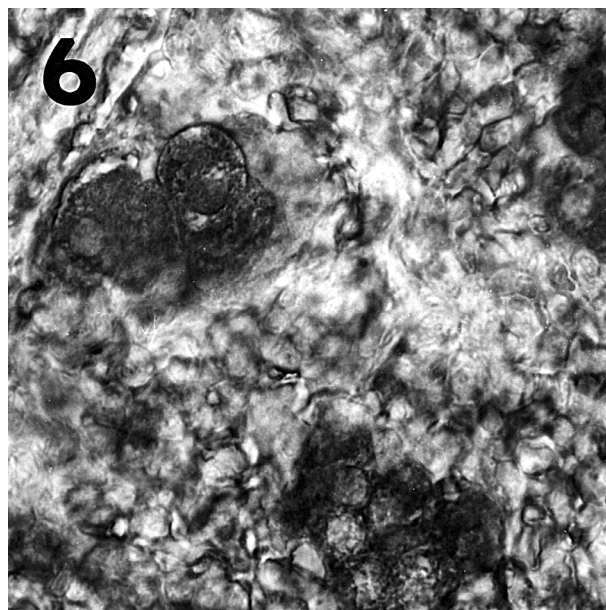


Figure 6. Solid cell nest. Biotinylated *Tritrichomonas mobilensis* lectin-reaction. Enlarged 100 times

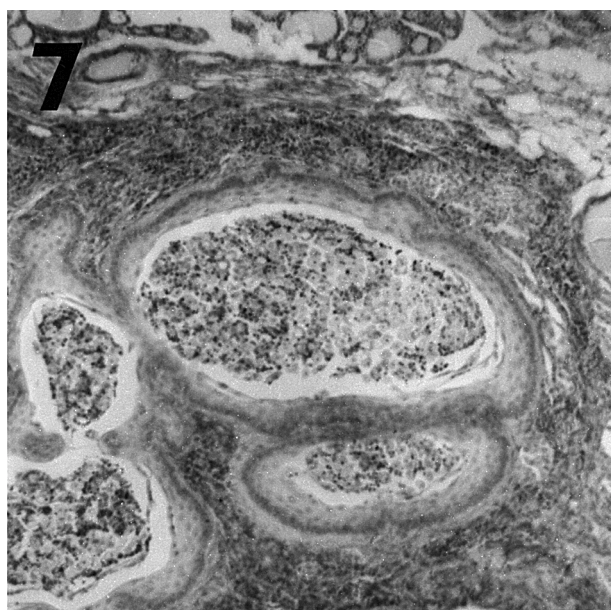


Figure 7. Lymphoepithelial cyst. Haematoxylin-erythrosin. Enlarged 10 times

licular cells found within the described lesions could indicate their reversal to the less-differentiated developmental stage, in spite of the fact that in our recent study no cases of thyroid neoplasms were encountered. TML-positive reaction revealed sialic acid regardless to its binding to the acceptor sugars. MAA-positive and SNA-non-positive reactions indicated that the terminal sialylation in the linkage a(2–3) to galactose prevailed.

#### Acknowledgements

We are grateful to Dr. Pavel Babál (Department of Pathology, University of South Alabama, Mobile, USA) for his kind gift of the biotinylated *Tritrichomonas mobilensis* lectin.

#### REFERENCES

- Beckner M.E., Shultz J.J., Richardson T. (1990): Solid and cystic ultimobranchial body remnants in the thyroid. *Arch. Pathol. Lab. Med.*, 114, 1049–1052.
- Cameselle-Teijeiro J., Varela-Durán J., Sambade C., Villanueva J.P., Varela-Núñez R., Sobrinho-Simões M. (1994 a): Solid cell nests of the thyroid. *Hum. Pathol.*, 25, 684–693.
- Cameselle-Teijeiro J., Varela-Durán J. (1994b): Carcinoma de tiroides. Propuesta de una teoría histogenética unitaria. *Patología*, 27, 53–61.
- Chetty R. (1990): Hürthle cell neoplasms of the thyroid gland: An immunohistochemical study. *Histopathology*, 17, 368–370.
- Ding K., Yamaguchi A., Goi T., Maehara M., Nakagawara G. (1997): Lectin-histochemical reactivity of sialic acid in breast cancer and its relationship to prognosis using *Limulus polyphemus* agglutinin. *Int. J. Oncol.*, 10, 759–763.
- Duprat A.M., Rougé P., Flottes S., Bley M. (1985): Lectin probes for visualization of cell differentiation markers on embryonic cells, p.193–201. In: Bøgg-Hansen T.C., Brebrowicz J. (eds.): *Lectins. Biology, Biochemistry, Clinical Biochemistry*. Vol. 4. Walter de Gruyter, Berlin. 193–201.

- Grimelius L. (1968): A silver nitrate stain for alpha-2 cells in human pancreatic islets. *Acta Soc. Med. Ups.*, 73, 243–270.
- Leblanc B., Paulus G., Andreu M., Bonnet M.C. (1990): Immunocytochemistry of thyroid C-cell complexes in dogs. *Vet. Pathol.*, 27, 445–452.
- Libbey N.P., Nowakowski K.J., Tucci J.R. (1989): C cell hyperplasia of the thyroid in a patient with goitrous hypothyroidism and Hashimoto's thyroiditis. *Am. J. Surg. Pathol.*, 13, 71–77.
- LiVolsi V.A. (1990): Pathology of thyroid disease. p.127–175. In: Folk S.A. (ed.): *Thyroid Disease: Endocrinology, Surgery, Nuclear Medicine, and Radiotherapy*. Raven Press, Ltd., New York.
- Martin V., Martin L., Viennet G., Challier B., Carbillet J.P., Fellmann D. (2000): "Solid Cell Nests" et pathologies thyroïdiennes. Étude retrospective de 1 390 thyroïdes. *Ann. Pathol.*, 20, 196–201.
- Martín-Lacave I., Bernabé R., Sampedro C., Conde E., Fernández-Santos J.M., San Martín M.V., Beato A., Galera-Davidson H. (1999): Correlation between gender and spontaneous C-cell tumors in the thyroid gland of the Wistar rat. *Cell Tissue Res.*, 297, 451–457.
- Mawdesley-Thomas L.E., Jolly D.W. (1967): Autoimmune disease in the Beagle. *Vet. Rec.*, 80, 553–554.
- Michal M., Plank L., Szepe P., Mukensnabl P. (1996): Lymphoepithelial lesions formed by lymphoma cell infiltration of the solid cell nests of the thyroid gland. *Histopathology*, 28, 569–571.
- Nishiyama I., Ogiso M., Oota T., Kimura T., Seki T. (1996): Developmental change in expression of highly polysialylated neural cell adhesion molecule in C-cells in rat thyroid gland. *Anat. Embryol.*, 194, 419–426.
- Ozaki O.K., Sugino K. (1991): Solid cell nests of the thyroid gland. *Virchows Arch. A-Pathol. Anat.*, 418, 201–205.
- Patnaik A.K., Lieberman P.H. (1991): Gross, histologic, and immunocytochemical study of medullary thyroid carcinoma in sixteen dogs. *Vet. Pathol.*, 28, 223–233.
- Phillips G.R., Krushel L.A., Crossin K.L. (1997): Developmental expression of two rat sialyltransferases that modify the neural cell adhesion molecule, N-CAM. *Dev. Brain Res.*, 102, 143–155.
- Ryška A., Vokurka J., Michal M., Ludvíková M. (1997): Intrathyroidal lymphoepithelial cyst. A report of two cases not associated with Hashimoto's thyroiditis. *Pathol. Res. Pract.*, 193, 777–781.
- Sata T., Zuber C., Roth J. (1990): Lectin-digoxigenin conjugates: a new hapten system or glycoconjugate cytochemistry. *Histochemistry*, 94, 1–11.
- Scheuba Chr., Kaserer K., Kotzmann H., Bieglmayer Chr., Niederle B., Vierhapper H. (2000): Prevalence of C-cell hyperplasia in patients with normal basal and pentagastrin-stimulated calcitonin. *Thyroid*, 10, 413–416.
- Tang K.N., Mansell J.L., Herron A.J., Sangster L.T. (1994): The histologic, ultrastructural, and immunohistochemical characteristics of a thyroid oncocyoma in a dog. *Vet. Pathol.*, 31, 269–271.
- Vajner L. (1997): Lymphocytic thyroiditis in beagle dogs in a breeding colony: findings of serum autoantibodies. *Vet. Med. – Czech*, 42, 333–338.
- Vajner L., Vortel V., Brejcha A. (1997): Lymphocytic thyroiditis in beagle dogs in beagle dogs in a breeding colony: histological findings. *Vet. Med. – Czech*, 42, 43–49.
- Vajner L., Uhlík J., Konrádová V., Zocová J. (2000): The effect of intravenously administered acetylcholine on the glycoconjugate composition in goblet cells of the tracheal epithelium in rabbits. *Acta Vet., Brno*, 69, 17–23.
- Vollenweider I., Hedinger C. (1988): Solid cell nests (SCN) in Hashimoto's thyroiditis. *Virchows Arch. A-Pathol. Anat. Histopathol.*, 412, 357–363.
- Watanabe I., Kobayashi K., Yamaguchi M., Kasai M. (1995): Multilocular lymphoepithelial cyst in the thyroid accompanied with a minute thyroid carcinoma. *Pathology Int.*, 45, 965–970.

Received: 00–12–15

Accepted after corrections: 01–04–04

---

*Corresponding Author:*

MVDr. Luděk Vajner, CSc., Institute of Histology and Embryology, 2nd Medical Faculty, Charles University, V úvalu 84, 150 06 Prague, Czech Republic

Tel. +420 2 24 43 59 82, fax +420 2 24 43 58 20, e-mail: Ludek.Vajner@lfmotol.cuni.cz

---