

Multiple pathologies of the feline uterus: a case report

R.A. SAPIERZYNSKI, I. DOLKA, A. CYWINSKA

Faculty of Veterinary Medicine, Warsaw University of Life Sciences, Warsaw, Poland

ABSTRACT: Uterine tumors are rare in cats, the most common clinical signs observed include presence of abdominal mass, weight loss, anorexia, pain, and vaginal bleeding in some cases. On the other hand, the most commonly diagnosed and thus the most important disease of feline uterus is cystic endometrial hyperplasia-pyometra complex (CEH-P). A 12-year-old, sexually intact, female domestic shorthaired cat was presented due to mild weight loss and recurring vaginal discharge. Data obtained during clinical examination, ultrasonography and basic blood tests suggested the presence of cystic endometrial hyperplasia with aseptic fluid accumulation in the uterine lumen. Macroscopic findings and light microscopic examination revealed complex uterine pathology, including: (1) cystic endometrial hyperplasia in uterine horns, (2) accumulation of mucoid fluid in lumen of uterine corpus (mucometra), (3) adenocarcinoma of the uterine corpus and (4) leiomyoma of the uterine cervix. Additionally, immunohistochemistry of both neoplastic tissues was made.

Keywords: adenocarcinoma; cat, immunohistochemistry; leiomyoma; uterus

Uterine tumors are rare in cats, constituting 0.29% of feline neoplasms reported in one study (Miller et al., 2003). The most common neoplasms in this species include leiomyomas, endometrial adenocarcinomas and leiomyosarcomas, although other lesions have also been described. In cats with uterine tumors the following clinical signs are presented: abdominal mass, weight loss, anorexia, pain, and vaginal bleeding in some cases (Miller et al., 2003; Cooper et al. 2006).

The most commonly diagnosed and thus the most important disease of the canine and feline uterus is cystic endometrial hyperplasia-pyometra complex (CEH-P). However, its prevalence decreases with the application of early ovariohysterectomies. CEH is characterized by endometrial hyperplasia with cyst formation; however, after suppurative infection pus accumulates in the uterine lumen, leading to CEH-P development. Cases of intensive mucous production by goblet cells in hyperplastic endometrial glands, when the lumen of the uterine cervix is strictly closed, and there is no bacterial infection are recognized as CEH-mucometra complex. The prevalence of hyperplastic endometrial abnormalities in sexually intact cats increases with age, and is most common in animals older than five years

(Potter et al., 1991). Clinically, these states, even those of the CEH-P complex may be asymptomatic, especially in milder cases. In 39% of cats the lesions were found circumstantially during routine ovariohysterectomies or at necropsy (Potter et al., 1991). In some cases abdominal distension may occur because of fluid accumulation in the uterus, and when ultrasonography is not performed a false diagnosis of uterine tumor can be made (Agudelo, 2005). The role of steroid hormones in the pathogenesis of the CEH-P complex in cats is controversial, but it seems that both disturbances in serum concentrations and changes in the expression of receptors in uterine tissues are involved (Misirlioglu et al., 2006). The prevalence of endometritis and pyometra in cats were associated with retained corpora lutea in at least one ovary (Potter et al., 1991).

MATERIAL AND METHODS

A 12-year-old, sexually intact, female domestic shorthaired cat was presented due to mild weight loss and recurring vaginal discharge. The owner mentioned that many years previously she had one episode of pregnancy but an abortion had been

carried out. After that, the cat regularly received contraceptive agents (injection of progesterone acetate). During clinical examination the following signs were defined: mild distension of abdomen, abdominal mass and dry discharge on the vulva. The ultrasonography revealed local widening of the uterine lumen (32-mm in diameter) and severe hyperplastic lesions within the endometrium of the uterine horns. Additionally, signs consistent with fluid accumulation in the uterine lumen were observed. No other abnormalities in the internal organs were found during ultrasonography. Morphological and biochemical blood parameters did not exceed reference values, with the exception of a mild elevation in asparagine transferase (57.1 IU/l; range 6–44 IU/l) activity. On the basis of physical examination, ultrasonography and blood analysis, cystic endometrial hyperplasia with fluid accumulation was diagnosed; however, due to the lack of leucocytosis pyometra was ruled out. Ovariohysterectomy was performed. Small (4–6 mm of diameter) thin-walled cysts filled with clear fluid were present in both ovaries. The uterus was enlarged; both uterine horns were 11–17 mm in diameter, the uterine corpus was markedly enlarged and filled with turbid, mucoserous, light brownish fluid. Additionally, an area of hyperplastic growth of endometrium in the abdominal aspect of the uterine corpus was found, and white-yellow, shiny and hard in palpation tumor affecting the uterine cervix was present. The uterus was resected and placed in 10% neutral buffered formalin for 24 h. Following fixation, numerous tissue samples were cut and processed routinely: embedded in paraffin sectioned at 4 µm, stained with hematoxylin and eosin, and additionally with the periodic acid Shift method.

For immunohistochemical staining, tissue samples were processed the same way. The expression of seven markers was investigated: cytokeratin (CK), Ki67, desmin, α -smooth muscle actin (α -sma), E-cadherin, estrogen receptor- α (ER- α), progesterone receptor (PR; Table 1). Briefly, 4-µm-thick sections on 2% silane coated slides were deparaffinized in xylenes and hydrated through graded alcohols. Antigen unmasking was performed by microwave heating at 600 W for 15 min in 10mM sodium citrate buffer, pH 6.0 (for CK and Ki67, PR) and Tris/EDTA buffer, pH 9.0 (for desmin, α -sma, E-cadherin, ER- α). Sections were allowed to cool in the buffer to room temperature for 20 min and were rinsed in deionized H₂O two times, for 2 min each. The endogenous peroxidase activity was blocked with 3% hydrogen peroxide for 5 min. Sections were incubated with antibodies for 1 h at room temperature in a humidity chamber, and after extensive washing in Tris-buffered saline (TBS) (0.1M Tris base, 0.9% NaCl, pH 7.4) were further incubated with a biotinylated secondary antibody. All following procedures were provided according to standard protocols with EnVision™ System (Dako, Denmark). The reactions were developed with 3-3'diaminobenzidine (Dako, Denmark), under microscopic control. Sections were counterstained with Mayer's hematoxylin, dehydrated, cleared in xylene and mounted. Positive and negative immunohistochemical controls were performed. Tissue sections of formalin-fixed, paraffin-embedded feline skin and uterus samples were treated as positive controls in every assay. Corresponding negative control sections were prepared by replacing only the primary antibody with TBS.

Table 1. Monoclonal antibodies used for immunohistochemical analysis

Antibody	Clone	Source	Specificity	Working dilution
Monoclonal mouse anti-human cytokeratin	MNF116	Dako, Denmark	CK	1/50
Monoclonal mouse anti-human Ki67 antigen	MIB-1	Dako, Denmark	Ki67	1/75
Monoclonal mouse anti-human desmin	D33	Dako, Denmark	Desmin	1/50
Monoclonal mouse anti-human α – smooth muscle actin	1A4	Dako, Denmark	α -SMA	1/50
Monoclonal mouse anti-human E-cadherin	NCH-38	Dako, Denmark	E-cadherin	1/50
Monoclonal mouse anti-human estrogen receptor α	1D5	Dako, Denmark	ER α	1/35
Monoclonal mouse anti-human progesterone receptor	PR 10A9	Immunotech, France	PR	ready-to-use

RESULTS AND DISCUSSION

Macroscopic findings and light microscopic examination revealed complex uterine pathology, including: (1) cystic endometrial hyperplasia in uterine horns, (2) accumulation of mucoid fluid in the lumen of the uterine corpus (mucometra), (3) adenocarcinoma of the uterine corpus and (4) leiomyoma of the uterine cervix (Figure 1). With regard to immunohistochemistry, cytokeratine expression was detected in the cytoplasm of endometrial glandular epithelium cells, adenocarcinoma cells, and mesothelium. Desmin expression was identified in endometrial and myometrial connective tissue, as well as in leiomyoma cells and additionally in stroma of adenocarcinoma stalks. Smooth muscle actin expression was detected in myometrium as well as in the leiomyoma cells but not in endometrial connective tissue and the cells of adenocarcinoma stalks. A weak to strong cell membrane positive reaction to cadherin E antibody was present in 25% to 75% of the cells in various areas of the adenocarcinoma (Figure 2A). Ki67 staining of adenocarcinoma epithelium revealed a positive reaction in about 40% of cells and 30% of cells in normal uterine endometrial epithelium. In contrast, expression of the Ki67 antigen was detected in about 5% of the cells in both the smooth muscle tumor and the myometrium layer. About 95% of normal epithelial cells in endometrial glands revealed a strong nuclear reaction with anti-ER antibody. Additionally, strong ER expression was present in 50% cells of the myometrium, and about

30% of connective tissue cells in the endometrium. Nuclear ER expression was observed in nuclei of the adenocarcinoma multifocally; however, the percentage of positive cells varied in respective tumor areas (from 25 to 50% of the cells in tumor parenchyma; Figure 2B). Furthermore, about 75% to 95% of leiomyoma cells expressed estrogen receptors within the nucleus (Figure 2C). The expression of PR was strong in normal uterine endometrial epithelium, myometrium (80–100% cells), leiomyoma cells (75–90% cells), stromal cells of endometrium (endometrial connective tissue – about 50% of cells), and absent in adenocarcinoma cells, and cells of the adenocarcinoma stalks.

This case study reports multiple and varied pathologic lesions in the feline uterus. Data obtained

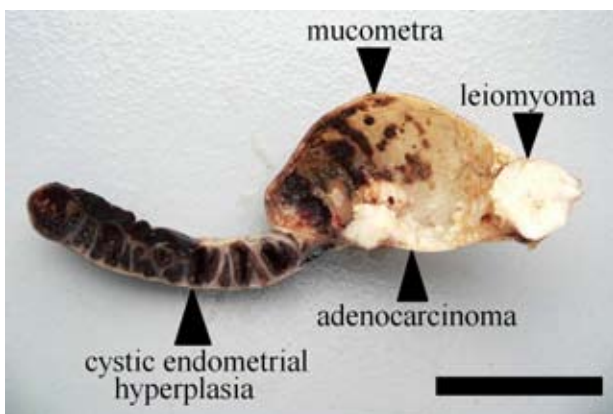


Figure 1. Uterus; sagittal section formalin fixed specimen; cat. Enlarged uterine corpus filled with turbid, mucoseous, fluid. Area of hyperplastic growth of endometrium in abdominal aspect of uterine corpus, white-yellow, shiny, tumor affecting uterine cervix; bar = 3 cm

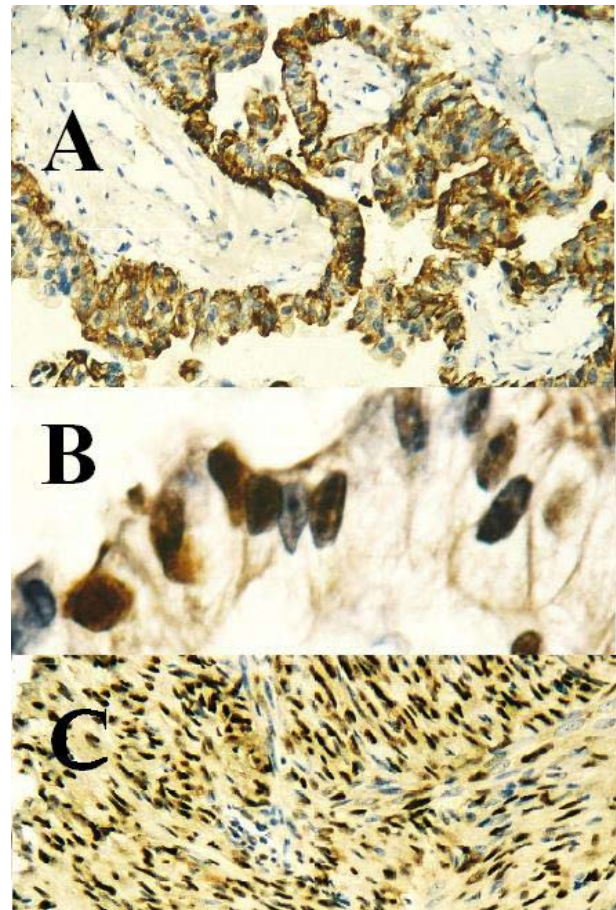


Figure 2. (A) E-cadherin expression (brown) in uterine adenocarcinoma cells (immunohistochemical stain, magnification 200×); (B) nuclear expression of estrogen receptors in uterine adenocarcinoma cells (immunohistochemical stain, magnification 400×); (C) nuclear expression of estrogen receptors in leiomyoma cells (immunohistochemical stain, magnification 200×)

during clinical examination, ultrasonography and basic blood tests suggested the presence of cystic endometrial hyperplasia with aseptic fluid accumulation in the uterine lumen. However, macroscopic and microscopic evaluation of tissue specimens revealed that the problem was more complex. Besides suspected and confirmed hyperplastic lesions of the endometrium and associated mucometra, two neoplasms, different in histological type and biological behavior were detected. The identification of two different areas of neoplastic growth in the feline uterus is unusual. Generally, uterine neoplasias are uncommon in this species. Leiomyomas and adenocarcinomas are diagnosed the most frequently (MacLachlan and Kennedy, 2002; Miller et al., 2003). Among specimens collected by the authors over a 8-year period, there were only three cases of uterine tumors in cats (two leiomyomas and one adenocarcinoma). On the other hand, these cases constitute 37.5% of all urogenital neoplasms recognized in both female and male cats (Sapierzynski et al., 2007). However, the coexistence of various types of neoplasms in the feline uterus has never been reported before. In women the simultaneous occurrence of leiomyosarcomas and leiomyomas has been described occasionally.

Discrimination between benign and malignant myometrial tumors can be difficult. Leiomyosarcomas are usually larger than nonmalignant counterparts, and cells within the tumors exhibit cellular atypia and a relatively high mitotic index (MacLachlan and Kennedy, 2002). However, even in cases with aggressive clinical course, microscopically no features of severe atypia may occur, and mitotic indices can be low. In these cases, therefore, discrimination between malignant and nonmalignant forms is based on biological behavior (Cooper et al., 2006). Similarly, in the presented case only a few areas of mild nuclear atypia and low numbers of mitotic figures were observed. However, immunohistochemistry was helpful in establishing the final diagnosis of leiomyoma, because using MIB-1 antibody, expression of the Ki67 antigen was detected in a very low number of the neoplastic cells, comparable with the number of the Ki67 positive cells in the normal myometrium. Similarly, only few Ki67 positive cells were present in the areas of the leiomyoma showing the features of nuclear atypia and mitoses. Additionally, strong expression of the ER- α in the nuclei of the smooth muscle tumor cells suggested a benign nature of the tumor. On the basis of this fact, the tumor was recognized

as a leiomyoma, and was discriminated from a leiomyosarcoma. Miller et al. (2003) reported that leiomyomas, but not leiomyosarcomas were positive for estrogen receptor- α . However, in the case of feline myxoid leiomyosarcomas weak positive nuclear reactions in some neoplastic cells have been noted (Cooper et al., 2006). Although there is no data on the presence of progesterone receptors in myometrial tumors in cats, the strong positive nuclear reaction, noted in most tumor cells in this study, may suggest the tumor cells were well differentiated. As was done in the presented case, the myometrial derivation of leiomyoma can be confirmed using anti-desmin antibody; however, the absence of desmin does not exclude the muscular origin of a tumor. For example, some leiomyosarcomas do not express desmin, but a positive immunohistochemical reaction for α -sma or Van Gieson staining is believed to confirm the muscular nature of the tumor (Cooper et al., 2006).

The results of immunohistochemical staining to detect tissue markers of adenocarcinoma in tumor samples were not surprising. As in the study of Miller et al. (2003), adenocarcinoma cells were positive for cytokeratins and negative for α -sma and desmin. A positive reaction to ER- α staining was observed in four of eight cases of feline endometrial adenocarcinomas examined by Miller et al. (2003). In the presented case there was mild to strong expression of estrogen receptors; however, it was observed multifocally, and positive cells were scattered in different areas of the tumor parenchyma. On the other hand, the expression of progesterone receptors in adenocarcinoma was observed neither in epithelial nor mesenchymal stromal cells. There is no published data on the expression of membrane cadherin E in feline uterine adenocarcinomas. A weak to strong positive cell membrane reaction was observed in a significant portion of the neoplastic cells; however, some of them did not express this adhesion protein suggesting a diminished ability of cell to cell binding. Unfortunately, a cluster of neoplastic cells within a blood vessel which was observed in a slide stained with hematoxylin-eosin was absent in slides stained with anti cadherin E antibody, making it impossible to conclude if the cells, which detached from the main tumor mass, had lost the expression of this adhesion protein. Decreased expression of cadherin E is believed to be an important factor associated with low differentiation grade in canine mammary gland tumors (Rodo and Malicka, 2008).

The development of mesenchymal tumors, especially sarcomas, in areas of long lasting inflammation is widely described in cats, for example in cases of vaccine-associated sarcomas and post-traumatic ocular sarcomas. In the presented case, two different types of tumors developed in the uterine corpus and no features typical for endometritis were observed microscopically. However, the adenocarcinoma was surrounded by histiocytic infiltration, resulting from the presence of calcification foci, so it cannot be excluded that long lasting inflammation contributed to endometrial neoplasia. The adenocarcinoma might also have been a consequence of hyperplastic lesions in endometrial glands. This hypothesis is hard to evaluate due to marked damage of the mucosa, especially the epithelium of the uterine corpus. However, the endometrium of undamaged mucosa in the uterine cervix appeared only slightly hyperplastic and cystic (first grade, of endometrial hyperplasia index; Agudelo, 2005). In the literature, a uterine sarcoma in an eight years old cat with long-standing pyometra has been reported (Jelinek, 2003).

The cause of CEH in the presented case was probably chronic exogenous progesterone stimulation with progesterone acetate, which was regularly administered to control sexual behavior. Another source of progesterone (i.e., corpora lutea) was not identified, although multiple small cysts within both ovaries were found. Potter et al. (1991) reported that 40% of cats with either pyometra or endometritis had corpora lutea. In cats these pathologies, but not endometrial hyperplasia are believed to be associated with retained corpora lutea. Endogenous and exogenous progesterone plays the main role in the development of cystic endometrial hyperplasia. This hormone promotes hyperplasia of the endometrium, increases the secretory activity of the endometrial glands and closure of the uterine cervix (Agudelo, 2005). The disease (at least at the microscopic level) is common in nulliparous queens older than three years and in other queens older than five years with no relationship to the number of parturitions (Agudelo, 2005). Advanced age, inhibition of estrus and thus lack of pregnancy and births all promoted CEH in this case; additionally, the presence of cervical mass caused accumulation of mucoid fluid in the uterine lumen. Alterations in the density and distribution pattern of receptors for steroid hormones in the uterine wall can be involved in the pathogenesis of CEH-P in bitches. The expression of progesterone

receptors was found in the glandular epithelium and myometrium of bitches with CEH/pyometra complex, but there was no reaction within the stromal cells. In the same animals estrogen receptors were detected in all layers of the uterine wall, and were the most numerous in the cells of the uterine stroma (Dhaliwal et al., 1999). Additionally, it was reported that in cats both ER and PR can play a role in the pathogenesis of cystic hyperplasia complex, but only the latter is involved in the pathogenesis of pyometra (Misirlioglu et al., 2006).

In women it is likely that sex hormones and steroid hormone receptors can be important in the development and maintenance of leiomyomas. One study reported that the contents of the ER and PR in these tumors were significantly higher than in normal myometrium; however, another confirmed it only in tumors localized to submucosa, but not in subserosa (Marugo et al., 1989). In this case of feline uterine leiomyoma, the expression of ER was higher in leiomyoma (90% of cells, in high power field of light microscope) than in nonaffected myometrium (about 50% of cells, evenly scattered, in all microscopic fields) Staining for the expression of progesterone receptors elicited a positive reaction in a similar percentage of cells in the leiomyoma and myometrium.

REFERENCES

- Agudelo C.F. (2005): Cystic endometrial hyperplasia-pyometra complex in cats. A review. *Veterinary Quarterly*, 27, 173–182.
- Cooper T.K., Ronnet B.M., Ruben D.S., Zink M.C. (2006): Uterine myxoid leiomyosarcoma with widespread metastases in a cat. *Veterinary Pathology*, 43, 552–556.
- Dhaliwal G.K., England G.C.W., Noakes D.E. (1999): Oestrogen and progesterone receptors in the uterine wall of bitches with cystic endometrial hyperplasia/pyometra. *Veterinary Record*, 145, 455–457.
- Jelinek F. (2003): Postinflammatory sarcoma in cats. *Experimental Toxicology and Pathology*, 55, 167–172.
- MacLachlan N.J., Kenedy P.C. (2002): Tumors of the genital systems. In: Meuten D.J. (ed.): *Domestic Animals*. Iowa State Press, Ames. 547–573.
- Marugo M., Centonze M., Bernasconi D., Fazzuoli L., Berta S., Giordano G. (1989): Estrogen and progesterone receptors in uterine leiomyomas. *Acta Obstetrica et Gynecologica Scandinavica*, 68, 731–735.
- Miller M.A., Ramos-Vara J.A., Dickerson M.F., Johnson G.C., Pace L.W., Kreeger J.M., Turnquist S.E., Turk J.R.

- (2003): Uterine neoplasia in 13 cats. *Journal of Veterinary Diagnostic Investigations*, 15, 515–522.
- Misirlioglu D., Nak D., Sevimli A., Nak Y., Ozyigit M.O., Akkoc A., Cangul I.T. (2006): Steroid receptor expression and HER-2/neu(c-erbB-2) oncoprotein in the uterus of cats with cystic endometrial hyperplasia-pyometra complex. *Journal of Veterinary Medicine Series A*, 53, 225–229.
- Potter K., Hancock D.H., Gallina A.M. (1991): Clinical and pathologic features of endometrial hyperplasia, pyometra, and endometritis in cats: 79 cases (1980–1985). *Journal of American Veterinary Medicine Association*, 198, 1427–1431.
- Rodo A., Malicka E. (2008): E-cadherin immunohistochemical expression in mammary gland neoplasms in bitches. *Polish Journal of Veterinary Sciences*, 11, 47–54.
- Sapierzynski R., Malicka E., Bielecki W., Krawiec M., Osinska B., Sendek H., Sobczak-Filipiak M. (2007): Tumors of the urogenital system in dogs and cats. Retrospective review of 138 cases. *Polish Journal of Veterinary Sciences*, 10, 97–103.

Received: 2009–07–03

Accepted: 2009–08–09

Corresponding Author:

Anna Cywinska, Warsaw University of Life Sciences, Faculty of Veterinary Medicine, Department of Preclinical Sciences, ul. Nowoursynowska 159c, 02-766 Warsaw, Poland
Tel. +48 225 936 153, Fax +48 225 936 152, E-mail: anna_cywinska@sggw.pl
