

The spinal nerves that constitute the plexus lumbosacrales of the red squirrel (*Sciurus vulgaris*)

A. AYDIN

Faculty of Veterinary Medicine, University of Firat, Elazig, Turkey

ABSTRACT: This study was aimed at investigating the lumbosacral plexus of squirrels (*Sciurus vulgaris*). Ten squirrels were used in this work. The animals were carefully dissected and the spinal nerves that constitute the lumbosacral plexus were examined. It was discovered that the lumbosacral plexus was formed by L6, L7, S1, S2 in nine animals and in the one remaining animal in addition to these branches rami ventralis of L4 and L5 were forming the plexus. The common root forming the last part of the lumbosacral plexus and giving branches dispersing to the hind limb was formed by the rami ventralis of L6, L7, S1, S2. Thus, in squirrels, the spinal nerves forming the lumbosacral plexus and the joining of these spinal nerves to each other differs from other rodents and mammals.

Keywords: lumbosacral plexus; nerves; the red squirrel (*Sciurus vulgaris*)

List of abbreviations

T = thoracal, L = lumbal, S = sacral, Ca = caudal

The rodents (*Rodentia*), which are the widest order of placental mammals, comprise more than half of all known mammals. The red squirrel is a representative of the *Sciuridae* family, which constitutes a group of the older *Rodentia* (Karol, 1963; Weichert, 1970; Kuru, 1987; Demirsoy, 1992). There are several studies concentrating on the spinal origins of brachial and lumbosacral plexus which give off nerve branches dispersing to the fore and hind limbs on the brachial plexus: in dogs (Miller et al., 1964), in cats (Getty, 1975), the wervet monkey (Booth, 1991), Chacma baboon (Booth et al., 1997), rabbit (Aslan, 1994; Yilmaz et al., 1995), rat (Green, 1968; Chiasson, 1980) and porcupines (Aydin, 2003, 2004); and on the lumbosacral plexus: in dogs (Miller et al., 1964; Getty, 1975.), rabbits (Barone et al., 1973; McLaughlin and Chiasson, 1987), rats (Green, 1968; Chiasson, 1980; Schmalbruch, 1986; Asato et al., 2000) and porcupines (Aydin, 2009; Aydin et al., 2009). In squirrels, the presence and localization of calbindin-D28k in the kidney and cerebellum (Aydin et al., 2005) and the morphology of circulus arteriosus cerebri (Aydin, 2008) were studied. But on the spinal origin of the lumbosac-

ral plexus there has been no investigation. Hence, this study aimed at investigating the spinal nerves forming the lumbosacral plexus in squirrels.

MATERIAL AND METHODS

Ten adult squirrels caught by villagers in Eastern Anatolia were used. Abdominal cavities were opened by an incision made along the linea alba and a dissection of the muscles. The symphysis pelvis of os coxae was cut with a costatom, and the pelvic cavity was opened. The organs of the cavum abdominis and pelvis were removed without the spinal nerves constituting the plexus lumbosacrales. The quadratus lumborum muscle, psoas minor and major muscles were dissected carefully. Subsequently, the ventral part of the corpus of lumbal and sacral vertebra from the last thoracal vertebra to the end of the sacrum was cleared completely. The origins of spinal nerves that constitute the plexus lumbosacrales in both the posterior legs were examined and pictures were taken of them. For the terminology, the *Nomina Anatomica Veterinaria* was used

(World Association of Veterinary Anatomists, 2005).

RESULTS

In the squirrels examined, L1, L2, L3 from the rami ventrales of the lumbar and sacral spinal nerves ran along separately, L4 and L5 were joined to each other by a thin branch, while L5 and L6 did not join to each other in nine animals. L5 with a thin branch coming from L4 formed the femoral nerve and the obturator nerve. In one animal a thin branch from L6 constituted the femoral and obturator nerve. The lumbosacral plexus was formed by L6, L7, S1, S2 in nine animals, while in the remaining one animal the rami ventrales of L4 and L5 constituted the lumbosacral plexus (Figures 1 and 2).

The ramus ventralis of L1 formed the cranial iliohypogastric nerve running just behind the last fluctuant costa.

The ramus ventralis of L2 formed the caudal iliohypogastric nerve running behind the cranial iliohypogastric nerve.

The ramus ventralis of L3 was a very thin branch and formed the ilioinguinal nerve.

The ramus ventralis of L4 separated into three branches. The first branch formed the lateral femoral cutaneous nerves, the second branch formed the genitofemoral nerves and the third branch joined to L5.

After taking a thin branch from L4, the ramus ventralis of L5 separated into the lateral and medial two branches, and there was a ramus muscularis in the middle part of these two branches. In nine animals the lateral branch formed the femoral nerve, while the medial branch formed the obturator nerve (Figure 1). In one animal, the branches coming from L6 contributed to the femoral and the obturator nerves (Figure 2).

Both of the ramus ventralis of L6 joined to L7 in nine animals. In one animal they separated into three branches and the first branch joined to the

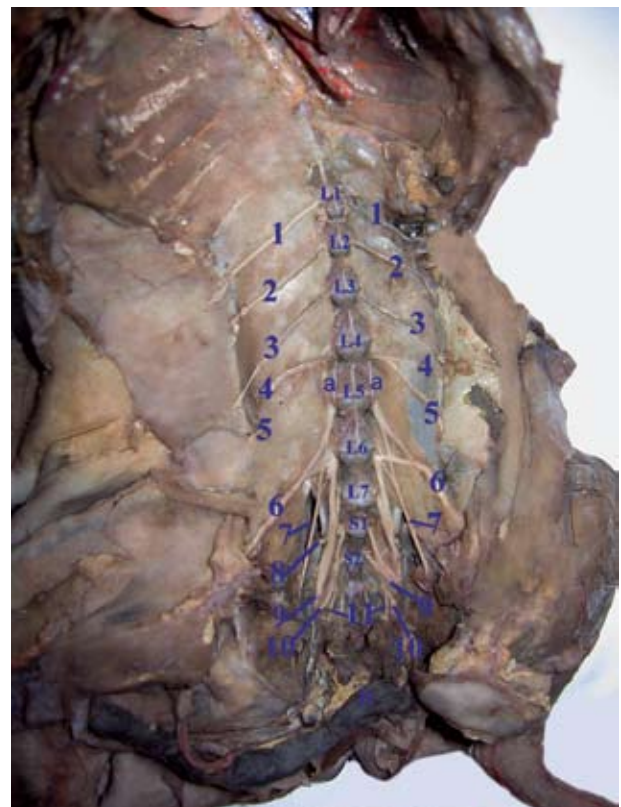
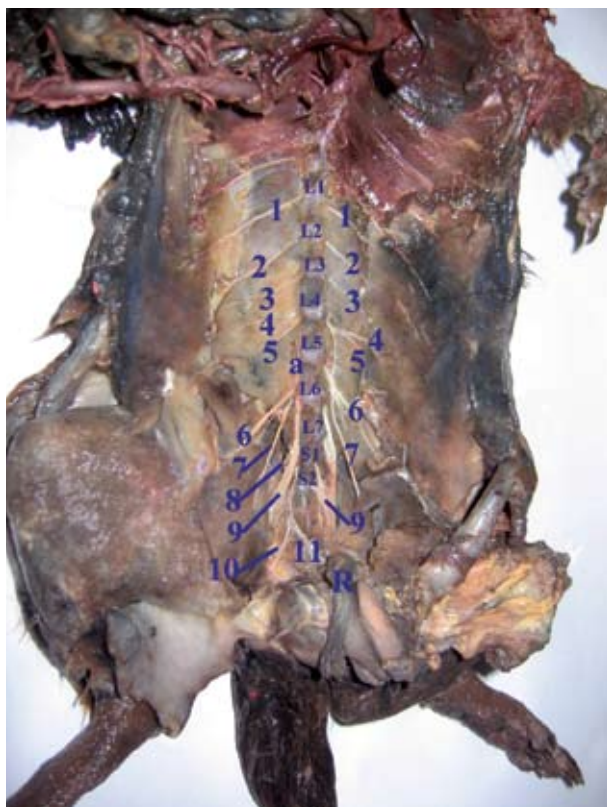

Figure 1 and 2. View from the cavum abdominal and pelvic of the lumbosacral plexus in the red squirrel (*Sciurus vulgaris*). a = branch knocking from L4 to L5; 1 = cranial iliohypogastric nerve; 2 = caudal iliohypogastric nerve; 3 = ilioinguinal nerve; 4 = lateral cutaneous femoral nerve; 5 = genitofemoral nerve; 6 = femoral nerve; 7 = obturator nerve; 8 = cranial gluteal nerve; 9 = the common root which was formed by the union of L6, L7, S1 and S2; 10 = pudendal nerve; 11 = caudal rectal nerve; R = rectum

femoral nerve, the second to the obturator nerve and the third branch which was a form of its continuation and the thickest, joined to L7.

The rami ventrales of L6, L7, S1 and S2 were joined to the formation of the common root giving off nerve branches dispersing to the hind limb and forming the last part of the lumbosacral plexus. In nine animals, the cranial gluteal nerve was the common root giving nerve branches to the hind limb, the pudental nerve, the caudal rectal nerve. In the remaining one animal, due to the joining of the rami ventrales of L4 and L5 to this formation, the lateral femoral cutaneous nerves, the genitofemoral nerves, the femoral and the obturator nerve originated from the lumbosacral plexus. After separating from the pelvic cavity, the common root giving nerve branches dispersing to the hind limb, gave the nerve branches as ramus muscularis, the caudal gluteal nerve, the caudal femoral cutaneous and the ischiadic nerve.

DISCUSSION

It has been reported that the lumbosacral plexus is formed by the union of the ventral rami of the last five lumbar (L2, L3, L4, L5, L6) and the first four sacral (S1, S2, S3, S4) nerves in cattle, the last two lumbar (L5, L6) and the first two sacral (S1, S2) nerves in sheep, the last four lumbar (L3, L4, L5, L6) and the first two sacral (S1, S2) nerves in goats (Getty, 1975; Tecirlioglu, 1983; Dursun, 2000), the last five lumbar (L3, L4, L5, L6, L7) and the first three sacral (S1, S2, S3) nerves in dogs (Miller et al., 1964; Getty, 1975), the last thoracal (T13), all the lumbar (L1, L2, L3, L4, L5, L6) and the first two sacral (S1, S2) nerves in rats (Green, 1968), the last thoracal (T15), all the lumbar (L1, L2, L3, L4) and the first two sacral (S1, S2) nerves in porcupines (Aydin et al., 2009), the last four lumbar (L4, L5, L6, L7) and the first three sacral (S1, S2, S3) nerves in cats (Getty, 1975), the last four lumbar (L3, L4, L5, L6) and the first three sacral (S1, S2, S3) nerves in guinea pigs (Cooper and Schiller, 1975), and the last four lumbar (L4, L5, L6, L7) and the first three sacral (S1, S2, S3) nerves in rabbits (McLaughlin and Chiasson, 1987). In the squirrels stated as C : 7, T : 12, L : 7, S : 3, Ca : 23 by Atalar and Yilmaz (2004) according to the vertebral formula, the formation of the lumbosacral plexus is constituted by the rami ventralis of the last two lumbar and first two sacral spinal nerves. Hence, this formation is partly in agreement with the findings of Getty

(1975), Tecirlioglu (1983) and Dursun (2000) in sheep, and is not consistent with the descriptions of the same authors in cattle and goats, and with the findings of other studies in dogs (Miller et al., 1964; Getty, 1975), in cats (Getty, 1975), in guinea pigs (Cooper and Schiller, 1975), in rats (Green, 1968), in porcupines (Aydin et al., 2009), and in rabbits (McLaughlin and Chiasson, 1987).

The common root which gives rise to the nerves innervating the posterior legs was reported to be formed by the union of L6, S1 and S2 in goats, L5, L6, S1 and S2 in sheep, L4, L5, L6, S1 and S2 in cattle (Getty, 1975), L6, L7, S1 and S2 in dogs (Miller et al., 1964; Getty, 1975), the last two lumbar (L4, L5) and the first three sacral (S1, S2, S3) in human (Ebraheim et al., 1997), the last four lumbar (L4, L5, L6, L7) and the first two sacral (S1, S2) in cats (Getty, 1975), the last lumbar (L6) and the first two sacral (S1, S2) in guinea pigs (Cooper and Schiller, 1975), the last three lumbar (L5, L6, L7) and the first three sacral (S1, S2, S3) in rabbits (McLaughlin and Chiasson, 1987), the entire last lumbar (L7) and the first sacral (S1), and slender branches from L6 and S2 in dogs (Tecirlioglu, 1983), and the entire L4 and S1, and a slender branch from S2 and L3 in porcupines (Aydin et al., 2009). There are many studies which report data regarding the formation of this common root in rats. Among these, Asato et al. (2000) reported that L4 and L5 always, and L6 rarely, contribute to the formation of the common root, while Vesjada and Hink (1980), Schmalbruch (1986) and Green (1968) found that L4, L5, L6, S1 and S2 are contributing nerves. In squirrels, due to the contribution of L6, L7, S1 and S2 there is a complete consistency with those findings in dogs (Miller et al., 1964; Getty, 1975; Tecirlioglu, 1983), partial consistency with reports from sheep due to the contribution of the last two lumbar and first two sacral (Getty, 1975; Tecirlioglu, 1983; Dursun, 2000), likewise in porcupines (Aydin et al., 2009), while the findings reported here are not in agreement with the data of Getty (1975) in cattle and goats, Ebraheim (2000) in humans, Getty (1975) in cats, Cooper and Schiller (1975) in guinea pigs, McLaughlin and Chiasson (1987) in rabbits, and Asato et al. (2000), Vesjada and Hink (1980), Schmalbruch (1986) and Green (1968) in rats.

As a result, the formation of lumbosacral plexus in squirrels is partly consistent with the findings of Getty (1975) Tecirlioglu (1983), and Dursun (2000) in sheep. The formation of the nerves dispersing in the hind limb as described herein is completely

consistent with the findings of Miller et al. (1964), and Tecirlioglu (1983) in dogs, the findings of Getty (1975), Tecirlioglu (1983) and Dursun (2000) in sheep regarding the last two lumbal and the first two sacral, while those of Aydin et al. (2009) on porcupines are partially consistent with our results. Thus, the data reported here differ from findings in other domestic mammals, rodents and in humans.

REFERENCES

- Asato F, Butler M, Blomberg H, Gordh T (2000): Variation in rat sciatic nerve anatomy: Implications for a rat model of neuropathic pain. *Journal of the Peripheral Nervous System*, 5, 19–21.
- Aslan K (1994): The comparative macroanatomic investigation on the brachial plexus of the native cat (*Felis domestica*) and White New Zealand rabbit (*Oryctolagus cuniculus*) (in Turkish). *Istanbul University, Faculty of Veterinary Medicine Journal*, 20, 197–208.
- Atalar O, Yilmaz S (2004): Anatomy of skeleton axiale of squirrel. *Indian Veterinary Journal*, 81, 305–311.
- Aydin A (2003): Brachial plexus of the porcupine (*Hystrix cristata*). *Veterinari Medicina*, 48, 301–304.
- Aydin A. (2004): Nerves originating from brachial plexus in the porcupine (*Hystrix cristata*). *Veterinari Medicina*, 49, 123–128.
- Aydin A (2008): The morphology of circulus arteriosus cerebri in the red squirrel (*Sciurus vulgaris*). *Veterinari Medicina*, 53, 272–276.
- Aydin A (2009): The dissemination of pelvic limb nerves originating from the lumbosacral plexus in the porcupine (*Hystrix cristata*). *Veterinari Medicina*, 54, 333–339.
- Aydin A, Karan M, Timurkaan S (2005): Presence and localization of calbindin-D28k in the kidney and Cerebellum of the red squirrel (*Sciurus vulgaris*). *Revue de Medecine Veterinaire*, 136, 434–436.
- Aydin A, Dinc G, Yilmaz S (2009): The spinal nerves that constitute the plexus lumbosacrales of porcupines (*Hystrix cristata*). *Veterinari Medicina*, 54, 194–197.
- Barone R, Pavaux C, Blin PC, Cuq P (1973): *Atlas of Rabbit Anatomy*. Masson & Cie, Paris. 158–174.
- Booth KK (1991): The brachial plexus in the vervet monkey (*Cercopithecus pygerythrus*). *Journal of Medical Primatology*, 20, 23–28.
- Booth KK, Baloyi FM, Lukhele OM (1997): The brachial plexus in the chacma baboon (*Papio ursinus*). *Journal of Medical Primatology*, 26, 196–203.
- Chiasson RB (1980): *Laboratory Anatomy of the White Rat*. W.C. Brown Company Publishers, Iowa. 99–102.
- Cooper G, Schiller AL (1975): *Anatomy of the Guinea Pig*. Harward, University Press, Cambridge, Massachusetts. 259–263.
- Demirsoy A (1992): *Rodentia*. The base rules of life. Me-teksan Anonim Sirketi, Ankara. 695–729.
- Dursun N (2000): *Veterinary Anatomy III*. Medisan Yayınevi, Ankara. 113–122.
- Ebraheim NA, Lu J, Yang H, Huntoon M, Yeasting RA (1997): Lumbosacral plexus: a histological study. *Acta Anatomica (Basel)*, 158, 274–278.
- Getty R (1975): *Sisson and Grossman's the Anatomy of the Domestic Animals*. 5th ed. W.B. Saunders Company, Philadelphia. 1137–1151 (Ruminants), 1705–1711 (Dog), 1719–1722 (Cat).
- Green CE (1968): *Anatomy of the Rat*. Hafner Publishing Company, New York and London. 128–170.
- Karol S (1963): *Dictionary of the Zoology Terms*. Turkish History Institution Press, Ankara. 192–193.
- Kuru M (1987): *Rodentia*. The Vertebrata Animals. Atatürk University, Basım, Erzurum. 551–564.
- McLaughlin CA, Chiasson RB (1987): *Laboratory Anatomy of the Rabbit*. W.C. Brown Company, Iowa. 92–94.
- Miller M, Christensen G, Evans H (1964): *Anatomy of the Dog*. W.B. Saunders Company, Philadelphia. 602–622.
- Schmalbruch H (1986): Fiber composition of the rat sciatic nerve. *Anatomical Record*, 215, 71–81.
- Tecirlioglu S (1983): *Comparative Anatomy of the Nerves System in Animals*. Ankara University Press, Ankara. 389 pp.
- Vejsada R, Hnik P (1980): Radicular innervation of hind-limb muscles of the rat. *Physiologia Bohemoslovaca*, 29, 385–392.
- Weichert CK (1970): *The Anatomy of the Chordates*. 4th ed. McGraw-Hill, London. 500–738.
- World Association of Veterinary Anatomists (1994): *Nomina Anatomica Veterinaria*. 4th ed. 122–125.
- Yilmaz O, Yildiz H, Yildiz B, Serbest A (1995): Morphological and morphometrical investigations on fascicle of ventral branches forming brachial plexus and nerves originating from plexus in White New Zealand Rabbits (*Oryctolagus cuniculus*) (in Turkish). *Hundredth year University Faculty of Veterinary Medicine Journal*, 6, 67–75.

Received: 2010–04–01

Accepted after corrections: 2010–04–14

Corresponding Author:

Dr. Ali Aydin, DVM, PhD, University of Firat, Faculty of Veterinary Medicine, Department of Anatomy, 23119 Elazığ, Turkey
Tel. +90 424 237 00 00-39 58, Fax +90 424 238 81 73, E-mail: aydina@firat.edu.tr; aliaaydin02@hotmail.com