

Inguinal-scrotal herniation and torsion of the large colon in an adult Andalusian stallion: a case report

F.J. MENDOZA, A. PEREZ-ECIJA, J.C. ESTEPA

Department of Animal Medicine and Surgery, University of Cordoba, Spain

ABSTRACT: A 3-year-old Andalusian stallion was referred to the Veterinary Teaching Hospital of the University of Cordoba due to acute onset of colic pain. At admission, the horse presented a pronounced distension of the inguinal and scrotal region which was cold and painful on palpation. On rectal palpation no small intestine gas distention was noticed, and the left large colon was detected protruding into the left internal inguinal ring. The percutaneous scrotal sonogram showed an intestinal loop which had moved into the scrotal bag close to the left testicle. The horse was diagnosed with indirect acquired left inguinal hernia. The necropsy revealed an impacted and twisted pelvic flexure in the vaginal space. To the authors' knowledge, this report is the first that describes a clinical case of inguinal-scrotal herniation and torsion of the pelvic flexure into the inguinal canal in an adult stallion associated with an impaction of the ascending colon.

Keywords: inguinal hernia; pelvic flexure; stud; impaction

Inguinal-scrotal herniation is a widely studied disease in horses, with the jejunum and ileum being the incarcerated segments in most cases (Mezerova et al., 2008b). On rare occasion, the large colon is the incarcerated part of the bowel introduced into the inguinal canal or scrotal bag.

Inguinal-scrotal hernia is a more common finding in males, but has also been described in females (Moorman and Jann, 2009). Although age and breed traditionally have not been related with higher predispositions, several authors have reported a higher prevalence in different breeds (Mezerova et al., 2003; Shoemaker et al., 2004).

In most of the cases the jejunum and ileum are the incarcerated segments, with a good prognosis and high rate of survival at discharge following the surgery (Mezerova et al., 2008a). Rarely, the large colon is the part of the bowel introduced into the inguinal canal or scrotal bag; foals are more likely to develop this herniation due to the fact that the inguinal canal is shorter and wider than in the mature horse (Robinson and Carmalt, 2009).

The more frequent acquired inguinal-scrotal hernias in mature horses are indirect, in which the herniated small intestine passes through the internal inguinal ring to the vaginal space, compromising

the testicle and its blood stream (Freeman, 2006; Schumacher and Perkins, 2010). Acquired direct herniations are common in foals, where the small intestine does not penetrate into the vaginal ring making a new path into the scrotal or preputial subcutaneous tissue (Freeman, 2006). In addition, the most common complication following castration is the evisceration of small intestine, usually jejunum and sometimes the omentum (Shoemaker et al., 2004; Carmalt et al., 2008), although a case of inguinal herniation of the ascending colon in a yearling four weeks after castration has been published recently (Ivens et al., 2009).

Several techniques to reduce inguinal herniation have been described. Briefly, the first method is manual external reduction where an intense massage is applied to the scrotal area (Wilderjans et al., 2008). This technique is used in those cases where the owner can not afford the surgical option. However, this procedure is prone to recidives and the absence of bowel wall viability assessment entails a higher prevalence of colic and peritonitis. Furthermore, sometimes it is very difficult to resolve the herniation, mainly in indirect inguinal hernias. A second technique is conventional surgery through an incision directly over the exter-

nal inguinal ring (herniotomy) and ventral midline laparotomy, if needed, to carry out traction of the bowel, resection of the ischemic-necrotic tissue or an anastomosis (Huskamp and Kopf, 1997; von Plocki et al., 2001; Toth and Hollerrieder, 2002). Finally, reduction by means of a laparoscopic technique represents a less invasive and novel method and involves closure of the internal inguinal ring by a peritoneal flap (Rossignol et al., 2007), mesh (Marien, 2001; Moorman and Jann, 2009) or normal ligation (Klohn and Wilson, 1996).

The objective of this clinical work is to report for the first time a case of acquired indirect inguinal-scrotal herniation of the large colon in a mature stallion.

Case description

History and clinical findings. A 3-year-old Andalusian stallion was referred to the Veterinary Teaching Hospital of The University of Cordoba due to acute onset of colic pain lasting six hours. The owner decided to send the animal to the hospital because of continuous watching of flanks, intense swelling, pawing and rolling. The stallion was up to date with regard deworming and vaccination procedures (influenza, tetanus and rhinoneumonitis). He was fed oats (2 kg twice a day), alfalfa hay *ad libitum*, and had free access to water. The horse had trained normally the same day and was not sexually active. No previous history of colic or other pathologies were reported. No treatment was administered by the referring veterinarian or by the owner prior to submission. At admission, the horse was colicky, presenting decreased skin elasticity, poor jugular distension, a slight toxic line in the oral mucous membrane, increased capillary refill time (roughly 4 s), tachycardia (90 beats/min), tachypnea (40 breaths/min), normal rectal temperature and cool limbs. No abdominal distension was noticed. The abdominal auscultation revealed the absence of borborygmi in the four quadrants. A pronounced swelling of the left inguinal area was detected, which was cold and painful on palpation. No reflux was obtained in response to nasogastric intubation.

On rectal palpation no small intestine gas distension was noticed, whereas a hard ascending colon, suggestive of impaction, was palpated. Moreover, the left colon extended from the midline of the abdominal cavity, attached to the ventral peritoneal wall, to the region of the left internal inguinal ring. A solid and large structure was palpated going

across the inguinal ring. The pelvic flexure could not be readily identified. The scrotal ultrasonography showed some free fluid content suggestive of hydrocele, and an intestinal loop into the scrotal bag close to the left testicle. The ultrasonographic appearance of the content of this loop was suggestive of impaction (Figure 1).

Laboratory findings. Analysis of the blood work revealed an increase of the packed cell volume (52%) and total protein concentration (7.2 g/dl). Leukocyte and platelet counts were within normal reference ranges. The biochemistry profile showed elevated creatinine (3.5 mg/dl), lactate (10 mmol/l) and fibrinogen (600 mg/dl) values. Abdominocentesis was performed which yielded a straw-yellow fluid with an enhanced leukocyte count ($10 \times 10^3/\mu\text{l}$) and peritoneal lactate concentration (8 mmol/l). The total protein and peritoneal glucose concentrations were within normal limits.

The clinical history, the laboratory results and ancillary findings supported the diagnosis of acquired left indirect inguinal herniation of the large colon.

Treatment. In order to facilitate the external exploration and complementary studies the animal was sedated with xylazine [0.5 mg/kg (0.25 mg/lb), *i.v.*]. While the tests were performed, the following treatment was administered: (a) hypertonic solution [NaCl 7.5%, 4 ml/kg (1.80 mg/lb), *i.v.*]; (b) polyionic isotonic crystalloid solution [Ringer lactate solution 80 ml/kg (36 ml/lb), *i.v.*], low molecular weight heparin [50 UI/kg (22.5 mg/lb), *s.c.*], potassium penicillin [22 000 UI/kg (9900 mg/lb) *i.v.*], and cryotherapy in the four limbs.

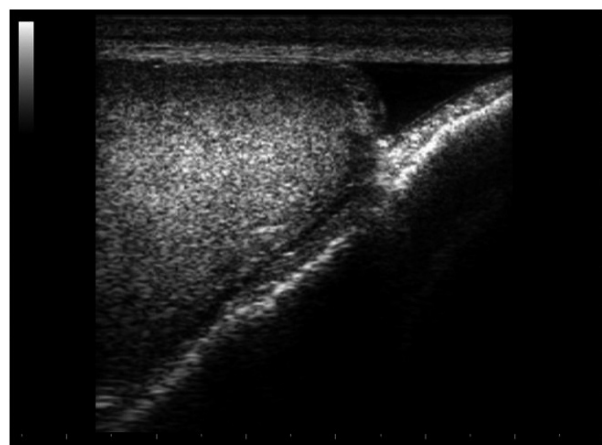


Figure 1. Sonogram of the left scrotal sac obtained with a 7.5 MHz linear transducer operating at a displayed depth of 5 cm showing an intestinal segment and the caudal part of the left testicle. The left side of the sonogram is cranial and the right side is caudal

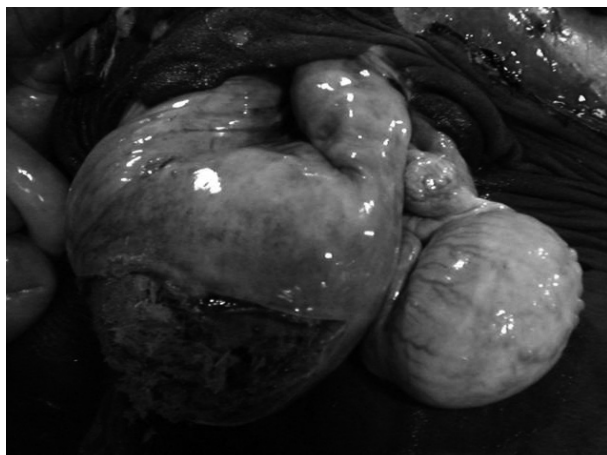


Figure 2. Open scrotal bag showing the herniated left large colon and the testicle in the vaginal space. The bowel presents multifocal petechial haemorrhages and transmural congestion with a compact content

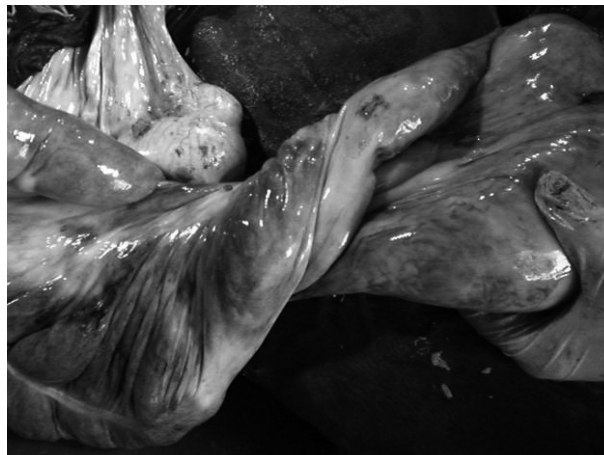

Figure 3. Detail of the colonic torsion in the vicinity of the inguinal ring. Both, proximal and distal segments show venous congestion and haemorrhages

Surgical resolution was recommended to the owner, but this was declined and the owner decided on sacrifice of the stud because of financial reasons.

Necropsy findings

During the necropsy an indirect inguinal-scrotal hernia consisting of a twisted left colon was the main finding. The scrotum appeared distended and oversized, and the testicles were difficult to identify. The mass protruding into the scrotum was revealed to be a 40 to 50 centimetre-long portion of large intestine, specifically the pelvic flexure. The bowel inside the hernia showed multifocal petechial haemorrhages in the serosa, oedema and congestion in submucosa and mucosa, and the content appeared to be compacted suggestive of impaction (Figure 2). Both deep and superficial inguinal rings of the left side were dilated (12 cm in diameter). Besides the intestinal loop contained in this inguinal canal, no other alteration was noticed. The contralateral inguinal rings were normal. A complete torsion (360°) of the left colon, 10 to 20 centimetres proximally to the pelvic flexure was noted near the external inguinal ring (Figure 3).

DISCUSSION AND CONCLUSIONS

A 3-year-old Andalusian stallion was presented with acute onset of abdominal pain. The physical examination revealed a distended left inguinal-scrotal

region, which was painful, cold and hard on palpation. Ancillary tests were performed in order to find the underlying cause. The most remarkable findings were: (a) large colon, introduced in the left inguinal ring; (b) an intestinal loop protruding into the scrotal bag close to the left testicle; (c) high leukocyte and lactate concentrations in the abdominal fluid. All the results described above support the diagnosis of acquired left inguinal-scrotal herniation of the large bowel. Due to financial constraints, the owner decided to euthanize the animal. The main gross findings in the necropsy were consistent with the final diagnosis.

These findings may be interpreted using a few different theories. The first one is that the ascending colon impaction could be the underlying cause of the pelvic flexure herniation, due to the increased weight of the large bowel which promoted the enlargement of the internal inguinal ring and subsequently the pelvic flexure incarceration and torsion. Another theory is that inguinal herniation occurred first resulting in an impaction. As has been reported previously, impaction can cause colon torsion. Nevertheless, this second theory appears less likely because the owner had not noted any scrotal distention and no sign of pain or discomfort was apparent before the acute onset.

Despite the fact that many different breeds have been described as having an elevated incidence of inguinal hernia, underlying causes remain elusive. In this sense, the case described here of an Andalusian breed may be part of a general tendency in this breed, as Andalusians have recently been described to have a high prevalence of inguinal herniation (Munoz et al., 2008). In male horses,

an important risk factor for developing this type of hernia is sexual activity, which is more prevalent in stallions than in geldings (Schumacher and Perkins, 2010). In the case reported here, however, the horse was not sexually active.

Colon torsion is also a well known disease of the large bowel in equine medicine. The risk factors for colon torsion include parasites, recent diet changes, sand accumulation, exercise, impaction, enteroliths, etc (Freeman, 2006). To our knowledge, this report is the first to describe colon torsion localized to the inguinal canal in horses.

The underlying cause of impaction in this animal was not determined. Although the role of several risk factors has been described (Freeman, 2006), in our case all these could be excluded from the reckoning.

In conclusion, this work describes the first clinical case of acquired inguinal-scrotal herniation and torsion of the pelvic flexure into the inguinal canal in a mature stallion associated with an impaction of the ascending colon.

REFERENCES

- Carmalt JL, Shoemaker RW, Wilson DG (2008): Evaluation of common vaginal tunic ligation during field castration in draught colts. *Equine Veterinary Journal* 40, 597–598.
- Freeman DE (2006): Small Intestine. In: Auer JA, Stick JA (eds.): *Equine Surgery*. 3rd ed. Elsevier Incorporation. 417–419.
- Huskamp B, Kopf N (1997): Diagnosis and treatment with respect to pathogenesis of incarceration (in German). *Praktische Tierarzt* 78, 217.
- Ivens PAS, Piercy RJ, Eliashar E (2009): Inguinal herniation of the large colon in a cob gelding four weeks after castration. *Veterinary Record* 165, 380–381.
- Klohn A, Wilson DG (1996): Laparoscopic repair of scrotal hernia in two foals. *Veterinary Surgery* 25, 414–416.
- Marien T (2001): Standing laparoscopic herniorrhaphy in stallion using cylindrical polypropylene mesh prosthesis. *Equine Veterinary Journal* 33, 91–96.
- Mezerova J, Zert Z, Kabes R, Jahn P (2003): Hernia inguinalis incarcerata in horses: 43 cases (in German). *Pferdeheilkunde* 19, 263–268.
- Mezerova J, Zert Z, Kabes R, Ottova L (2008a): Analysis of therapeutic results and complications after colic surgery in 434 horses. *Veterinari Medicina* 53, 12–28.
- Mezerova J, Zert Z, Kabes R, Ottova L (2008b): Analysis of clinical and perioperative findings in 576 horses subjected to surgical treatment of colic. *Veterinari Medicina* 53, 29–42.
- Moorman VJ, Jann HW (2009): Polypropylene mesh repair of a unilateral, congenital hernia in the inguinal region in a Thoroughbred filly. *Canadian Veterinary Journal* 50, 613–616.
- Munoz E, Arguelles D, Areste L, Miguel LS, Prades M (2008): Retrospective analysis of exploratory laparotomies in 192 Andalusian horses and 276 horses of other breeds. *Veterinary Record* 162, 303–306.
- Robinson E, Carmalt JL (2009): Inguinal Herniation of the ascending colon in a 6-month-old Standardbred colt. *Veterinary Surgery* 38, 1012–1013.
- Rossignol F, Perrin R, Boening KJ (2007): Laparoscopic hernioplasty in recumbent horses using transposition of a peritoneal flap. *Veterinary Surgery* 36, 557–562.
- Schumacher J, Perkins J (2010): Inguinal herniation and rupture in horses. *Equine Veterinary Education* 22, 7–12.
- Shoemaker R, Bailey J, Janzen E, Wilson DG (2004): Routine castration in 568 draught colts: incidence of evisceration and omental herniation. *Equine Veterinary Journal* 36, 336–340.
- Toth J, Hollerrieder J (2002): Diagnosis and treatment of hernia inguinalis incarcerata (in Hungarian). *Magyar Allatorvosok Lapja* 124, 71–81.
- Von Plocki KA, Furkert-Korsa B, Gieriek A (2001): Abdominal herniotomy as an alternative method of inguinal hernia treatment for stallions (in Polish). *Medycyna Weterynaryjna* 57, 658–661.
- Wilderjans H, Simon O, Boussauw B (2008): Strangulated hernias in 63 horses. Results of manual closed non-surgical reduction followed by a delayed laparoscopic closure of the vaginal ring. In: *Proceedings of the 10th International Congress of World Equine Veterinary Association*, January 28 – February 1, 2008, Moscow, Russia, 360–364.

Received: 2010–04–15

Accepted after corrections: 2010–06–08

Corresponding Author:

Francisco J Mendoza DVM, PhD, MS, University of Cordoba, Department of Animal Medicine and Surgery, Ctra. Madrid-Cadiz km 396, 14014 Cordoba, Spain
E-mail: pv2megaf@uco.es
