Hepatopancreatic ganglioneuroma in a young dog: a case report

R. Zafra, M.J. Bautista, J. Perez, P.J. Ginel, R. Lucena

Faculty of Veterinary Medicine, University of Cordoba, Spain

ABSTRACT: The clinical, pathological and immunohistochemical features of a hepatobiliary and pancreatic ganglioneuroma in a seven-month-old dog are described. The dog presented progressive weight loss, anorexia and abdominal pain. At laparoscopic examination numerous whitish nodules ranging from 0.5 to 1 cm in diameter were found in the peripancreatic tissues, the bile duct system and perihepatic tissues. Due to poor prognosis the dog was euthanized and necropsy was conducted. Tumour nodules were not noted in the other examined abdominal organs. Microscopically, the nodules were composed of large, well differentiated neurons embedded in an abundant stroma of nerve fibres and connective fibrous tissue. Through immunohistochemistry analysis, neurons were found to express neurofilaments and did not express S-100 protein. The histopathological and immunohistochemical features were consistent with a diagnosis of ganglioneuroma. This case is atypical as the majority of reported canine ganglioneuromas involve the gastrointestinal tract. The early age of the dog is also considered to be atypical for this tumour.

Keywords: ganglioneuroma; dog; immunohistochemistry; liver; pancreas

Ganglioneuromas are rare, benign tumours arising from the peripheral nervous system (sympathetic nervous system and adrenal medulla) and are composed of a mixture of ganglion cells, Schwann cells and nerve fibres (Hermeyer et al., 2007). Ganglioneuromas have only been reported in a few cases in adult dogs (Hawkins and Summers, 1987; Fairley and McEntee, 1990; Ribas et al., 1990; Schueler et al., 1993; Reimer et al., 1999; Hermeyer et al., 2007), and mainly involve the gastrointestinal tract. Only one case arising from the Vater's papilla to the common bile duct, perihepatic tissue and duodenum has been reported (Van Den Ingh and Routhuizen, 1984). The aim of this work was to describe the clinical, histopathological and immunohistochemical features of an hepatobiliar and pancreatic ganglioneuroma in a seven-month-old dog that did not affect the gastrointestinal tract.

Case description

A seven-month-old male Terranova breed dog was referred to the Veterinary Teaching Hospital of the University of Cordoba because of a two-month history of poor appetite and weight loss. Physical examination revealed jaundice, depression, severe dehydration and marked abdominal pain located in the hepatic region. Blood analysis revealed increased serum levels of AST (59 UI/l), ALT (131 UI/l) and ALP (182 UI/l), α-amylase (3316 UI/l), total bilirubin (5.73 mg/dl) and cholesterol (550 UI/l). Results from urinalysis showed a light increase in urobilinogen and severe bilirubinuria. Abdominal ultrasound showed a dilated bile duct system and the liver was found to have a heterogeneous consistency. Therapy for a hepatocholangiopathy was commenced which included the administration of intravenous fluid, parenteral amoxiciline (20 mg/kg/12 h), ursodeoxycholic acid (10 mg/kg SID) as well as vitamin complex with carnitine and S-adenosyl metionine (PO, SID). Despite the treatment, ten days later the clinical status of the dog worsened and the animal presented with severe hepatic pain, jaundice, sporadic vomiting and soft yellowish faeces. Blood analysis showed anaemia, leukocytosis, higher levels of serum AST (106 UI/l), ALT (280 UI/l), ALP (264 UI/l) and total bilirubin (6.70 mg/dl). Once the

Supported by the Grant Junta de Andalucia (Grant No. AGR262).

dog was stabilized, an exploratory laparotomy was performed. The liver showed a heterogeneous colour with wide pale areas and the gallbladder and common bile duct were severely dilated with fluid content and thickened wall. Numerous whitish nodules ranging from 0.5 to 1 cm in diameter had infiltrated the peripancreatic tissues, the bile duct system and perihepatic tissues. The abdominal lesions observed suggested a neoplastic process without the possibility of surgical resection. Due to this poor prognosis, the owner declined any treatment and the dog was euthanized and necropsy was carried out.

Tissue samples from the liver, pancreas, gallbladder and bile ducts, as well as from other viscera, were fixed in 10% formalin and embedded in paraffin wax. Four-µm-thick tissue sections were stained using haematoxylin and eosin, periodic acid-Schiff Alcian blue reaction, Toluidin blue and Bielschowsky staining. The avidin-biotin-peroxidase (ABC) method (Vector, Burlinghame, USA) and polyclonal antibody against human S-100 protein (Dako, Denmark) as well as monoclonal antibody against human neurofilament protein (Eurodiagnostica, The Netherlands) were used for the immunohistochemical study. Normal brain tissue from a dog was used as a positive control for both primary antibodies. Primary antibodies were substituted with TBS or non-immune isotype matched sera as negative controls.

Grossly, two whitish and firm masses ranging from 5 × 1 × 1 cm were found around the cardias hiatus protruding into the thoracic cavity and extending to the peripancreatic tissue. These did not adhere to the stomach surface. In addition, multiple, gray, poorly defined masses ranging from 0.2 to 1 cm in diameter were found in the pancreas and liver, mainly in the vicinity of large bile ducts and the gallbladder.

Microscopically, these masses were composed of variable amounts of neuron cell bodies (ganglion cells) embedded in an abundant stroma of nerve fibres and fibrous tissue (Figure 1). Neurons showed spindle, pyramidal and stellate-shapes, with large, eccentric, vesicular nuclei with prominent nucleoli and moderate to abundant cytoplasm with variable amounts of Nissl granules; occasional mitotic figures were observed in this cell population (Figure 2). Neuronal somas and axons were strongly stained using the Bielschowsky technique. The immunohistochemical study showed that the PAb S-100 protein reacted only with nerves entrapped in the stroma, while a strong cytoplasmic immunolabelling against MAb neurofilament protein was found in the neuronal soma and nerves entrapped in the stroma (Figure 3). Neurons were embedded in an extensive stroma composed of interlacing fascicles of nerve fibres arranged in a wavy pattern and containing axons. Parallel to the axons, spindle-shaped cells with oval nuclei resembling Schwann cells were found. Schwann cells and axons were often included in a myxomatous matrix with variable amounts of collagen fibres. The neoplastic tissue occupied large areas of the pancreas compressing glandular tissue, whereas in the liver the tumour

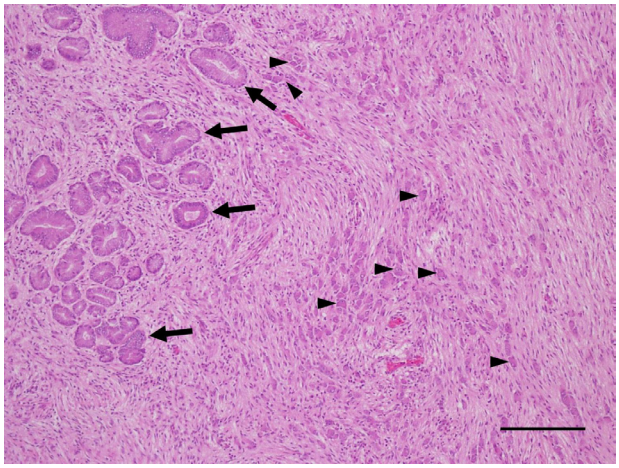

Figure 1. Photomicrograph of a tumour mass surrounding the gallbladder and common bile duct (arrows), composed of neurons (arrowheads) embedded in an abundant connective stroma; HE; bar = 200 µm

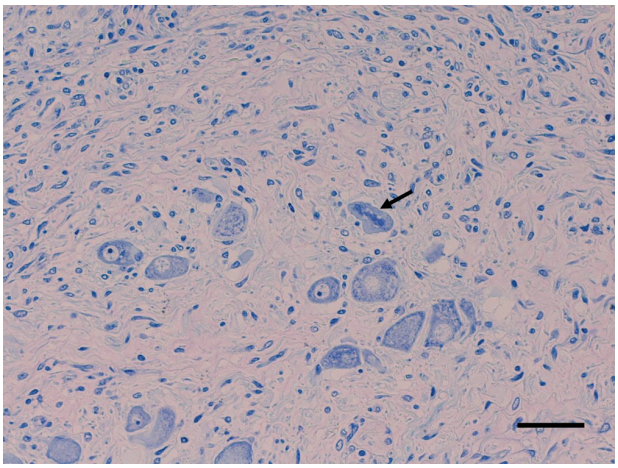

Figure 2. Detail of the tumour mass shown in Figure 1. Note large cells resembling ganglion cells with abundant cytoplasm containing Nissl substance and hyperchromatic, large nucleoli, one of which contains a mitotic figure (arrow); Touluidine blue; bar = 30 µm

Figure 3. Same tumour mass as in Figures 1 and 2. Strong immunolabelling to anti-neurofilament protein is observed in the cytoplasm of neuronal soma and axons (arrows) in some nerves located among the abundant stroma. ABC method, Mayer's haematoxylin counterstain; bar = 30 μm

occupied large areas surrounding large bile ducts and the gallbladder and penetrated into the liver parenchyma occupying portal spaces, where bile duct proliferation was found. Auerbach's plexus of the stomach and duodenum were enlarged with increased numbers of ganglion cells. The gastrointestinal tract and other viscera showed no changes.

Although the present case presented an infiltrative growth in the liver, the cellular atypia and mitotic index of ganglion cells were moderate, and results of the immunohistochemical studies were consistent with a diagnosis of ganglioneuroma. In dogs, ganglioneuroma is a rare neoplasm reported in adults and arises from the spinal cord (Schueler et al., 1993), the bifurcation of left common carotid artery (Ferrel et al., 1964), the Vater's papilla (Van Den Ingh and Routhuizen, 1984), the mediastinum (Hawkins and Summers, 1987), the intestinal tract (Fairley and McEntee, 1990; Ribas et al., 1990; Reimer et al., 1999), and the skin (Hermeyer et al., 2007). The case reported here is atypical because of the pancreatic and hepatobiliar location without gastrointestinal tract infiltration.

DISCUSSION AND CONCLUSIONS

Previous reports in young dogs hypothesized about the congenital aetiology of ganglioneuromas (Hawkins and Summers, 1987; Fairley and McEntee, 1990; Ribas et al., 1990; Reimer et al., 1999). An embryonic origin, presumably from primitive neuroectodermal cells has been posited (Reimer et al., 1999). In the present case, the age and the onset of clinical signs might support a developmental anomaly as the most likely pathogenesis.

The most probable primary location of the tumour in this dog was considered to be ganglia of the autonomic nervous system near the hepatopancreatic areas where the largest tumour masses were located. The tumour would have progressed along the efferent nerves of the affected ganglia to the thorax where the two cylindrical shaped masses were found near the hiatus. However, the tumour did not extend to the gastrointestinal tract. It is likely that if the health of the dog had not quickly worsened, the tumour could have progressed and infiltrated the digestive tract. Conversely, in the three reported cases in young dogs the gastrointestinal tract was the primary location (Fairley and McEntee, 1990; Ribas et al., 1990; Reimer et al., 1999), whereas in the adult dog (Van Den Ingh and Routhuizen, 1984) the tumour initiated from the Vater's papilla to the duodenum.

As described (Hermeyer et al., 2007), in ganglioneuromas severe clinical signs can be manifested. In the present case, clinical signs could be explained by cholangiohepatic lesions with the extrahepatic cholestasis, as reported previously (Van Den Ingh and Routhuizen, 1984). Results of biochemical analyses were similar to those described in the dog with Vater's papilla ganglioneuroma (Van Den Ingh and Routhuizen, 1984). The normal serum pancreatic profiles could be explained by the lack of tumour infiltration through the pancreatic parenchyma.

The immunophenotype of the proliferated neurons (S-100 protein-negative and neurofilament-positive) found in the present work is in agreement with the results of previous cases of human and animal ganglioneuromas which showed immunoreaction for NF, whereas S-100 protein labelled only nerve and spindle cells identified as Schwann cells (Hawkins and Summers, 1987; Ribas et al., 1990; Hermeyer et al., 2007).

In conclusion, the present work is the first report of a hepatobiliary and pancreatic ganglioneuroma in a young dog without gastrointestinal involvement. The tumour initiated in the hepatopancreatic region and extended through the thoracic cavity. The poor clinical status of the animal, the lack of response to therapy, together with the widespread extension of the tumour in the abdominal cavity

meant that the case was not amenable to surgical resection. The dog was thus euthanized at the owner's request.

REFERENCES

Fairley RA, McEntee MF (1990): Colorectal ganglioneuromatosis in a young female dog. Veterinary Pathology 27, 206–207.

Ferrell JF, Hunt RD, Nims RM (1964): Cervical ganglioneuroma in a dog. Journal of the American Veterinary Medical Association 144, 508–512.

Hawkins KL, Summers BA (1987): Mediastinal ganglioneuroma in a puppy. Veterinary Pathology 24, 283–285.

Hermeyer K, Kuhn M, Kuchelmeister K, Laiks C, Baumgartner W, Wohlsein P (2007): Multiple cutaneous ganglioneuromas in a dog. Veterinary Dermatology 18, 360–364.

Reimer ME, Reimer MS, Saunders GK, Johnston SA (1999): Rectal ganglioneuroma in a dog. Journal of the American Animal Hospital Association 35, 107–110.

Ribas JL, Kwapien RP, Pope ER (1990): Immunochemistry and ultrastructure of intestinal ganglioneuroma in a dog. Veterinary Pathology 27, 376–379.

Schueler RO, Roush JK, Oyster RA (1993): Spinal ganglioneuroma in a dog. Journal of the American Veterinary Medical Association 203, 539–541.

Van Den Ingh TSGAM, Routhuizen J (1984): Ganglioneuroma of Vater's papilla and extrahepatic cholestasis in a dog. Veterinary Pathology 21, 254–256.

Received: 2011–01–12
Accepted after corrections: 2011–02–14

Corresponding Author:

Jose Perez Arevalo, Universidad de Córdoba, Facultad de Veterinaria, Departamento de Anatomía y Anatomía Patológica Comparadas, Campus Universitario de Rabanales, Ctra. Madrid-Cadiz km 396, 140 14 Córdoba, Spain
Tel. +34 957218178, Fax +34 957218682, E-mail: an1pearj@uco.es