

Immunohistochemical profile of multicentric cutaneous epitheliotropic T-cell lymphoma with generalised lymphadenopathy in a Holstein-Friesian cow: a case report

I. OTROCKA-DOMAGALA, Z. PROCAJLO, K. PAZDZIOR, M. GESEK, T. ROTKIEWICZ, W. SZWEDA

Veterinary Medicine Faculty, Warmia and Mazury University in Olsztyn, Poland

ABSTRACT: Cutaneous epitheliotropic T-cell lymphoma with progression to superficial and internal lymph nodes and the spleen was diagnosed in a two-year-old Holstein-Friesian cow. The skin lesions included multiple hypotrichous to alopecic nodules, often with ulceration, which first appeared three months after calving and progressed quickly to cover the entire body. The cow was euthanized one month later. The ELISA test excluded bovine leukaemia virus infection. Histologically in the epidermis, the formation of Pautrier's microabscesses and in the dermis, dense neoplastic infiltration with mild folliculotropism was observed. Similar neoplastic cells were present in the histological sections of lymph nodes and spleen. Immunohistochemical analysis was performed using CD3, CD79 α cy, HLA-DR, WC1-N3 and Ki67 antibodies. Immunophenotyping results (CD79 α cy–, CD3+, WC1-N3–) confirmed the $\alpha\beta$ T-cell origin of neoplastic cells. The mean Ki67 index among neoplastic cells was 15.3%. On the basis of the immunohistochemical and histopathological results, the first case in Poland of cutaneous epitheliotropic T-cell lymphoma in a cow was confirmed. Additionally, MHC class II expression on approximately 10.4% of lymphoma cells was associated with a poor clinical prognosis. However, the up-regulation of MHC class II expression on accompanying cells suggested tumour immune surveillance, an antigen-specific immune response or immunosuppression. However, further investigations are needed to confirm these suspicions.

Keywords: cattle; cutaneous epitheliotropic lymphoma; T-cell lymphoma; immunohistochemistry

Primary cutaneous lymphomas (PCLs) in humans are defined according to the World Health Organization and European Organization for the Research and Treatment of Cancer Classification as non-Hodgkin's lymphomas that present on the skin with no evidence of extracutaneous disease at least six months after diagnosis and disease progression (Burg et al. 2006; Willemze and Dreyling 2010). Within the group of PCLs, distinct types of cutaneous T-cell lymphomas (CTCL) and cutaneous B-cell lymphomas (CBCL) can be distinguished (Willemze and Dreyling 2010). Cutaneous T-cell lymphoma in humans, most commonly seen as mycosis fungoides (MF), is a relatively common clonal expansion of T helper cells and, more rarely, T suppressor/killer cells or NK cells (Burg et al. 2006). Cutaneous lymphomas reported in most domestic

and many animals in the wild are usually divided into epitheliotropic and non-epitheliotropic categories (Gross et al. 2005; Valli 2007). Epitheliotropic lymphomas are progressive diseases characterised by neoplastic infiltration of the epidermis and adnexal structures and are limited to lymphomas derived only from T-cells. Clinically, patch, plaque and tumour stages can be differentiated; however, there is often progression from one stage to the other (Gross et al. 2005; Valli 2007). In the tumour stage, lymph nodes and other organs may be affected (Valli 2007). Epitheliotropic lymphoma in animals is subclassified as "classical" mycosis fungoides and d'émblée form, Sézary syndrome and pagetoid reticulosis (Woringer-Kolopp) (Gross et al. 2005; Valli 2007). MF in cats and dogs is composed of CD3+ T-cells, with positive CD8 expression in

approximately 80% of cases and double-negative (CD4⁻, CD8⁻) expression in the remaining 20%. In pagetoid reticulosis, these CD3⁺ lymphocytes have a dgT-cell origin, but in MF, they are dg- or $\alpha\beta$ T-cells (Gross et al. 2005). Non-epitheliotropic cutaneous lymphomas appear to be less common in animals. They are characterized by predominantly deep dermal and subcutaneous neoplastic lymphocyte infiltration and classified as vasotropic or vaso-invasive non-epitheliotropic lymphomas, intravascular lymphomas, or T-cell-rich B-cell lymphomas. The vast majority of cutaneous canine and feline non-epitheliotropic lymphomas derive from T-cells. Canine non-epitheliotropic CD3⁺ T-cell lymphomas comprise either CD8⁺ or double-negative (CD4⁻, CD8⁻) lymphocytes. The expression of CD4 and CD8 is variable in cats (Valli 2007). The pathogenesis of cutaneous lymphomas most likely involves multiple steps, has a multifactorial nature and starts as a hyper-reactive, inflammatory process due to various stimuli that may be genetic (numerical and structural chromosomal abnormalities), environmental, infectious (herpes- and retroviruses, bacteria, chlamydia) or immunological (vaccination or allergen hypersensitivity, drugs or arthropod reactions) (Burg et al. 2006).

MHC class II molecules play a pivotal role in the induction and regulation of an antigen-specific immune response. They are expressed mainly on antigen-presenting cells (APCs) including B-cells, monocytes, macrophages, dendritic cells and thymic epithelial cells (Reith et al. 2005). Other cells such as fibroblasts, endothelial cells, and epithelial cells express MHC class II molecules in environments rich in inflammatory cytokines, particularly interferon γ (IFN γ), which are produced during

infection, inflammation or trauma (Holling et al. 2004a; Reith et al. 2005). Moreover, activated T-lymphocytes also express these molecules in both humans and animals (Holling et al. 2004b). Furthermore, the level of MHC class II expression in some tumours, especially those of hematopoietic origin, correlates with increased immunogenicity and reduced tumourigenicity. The loss of MHC class II expression could contribute to the ability of neoplasma cells to escape host immune surveillance and corresponds with a poor clinical prognosis (Reith et al. 2005).

Case description

A two-year-old Holstein-Friesian cow developed small, firm, hypotrichous to alopecic cutaneous tumours around the neck and both scapular regions along lymphatic vessels three months after calving (Figure 1A). The lesions increased in size and covered practically the whole body surface, surrounding even the anus and the vulva. The lesions had a cauliflower-like appearance, varied from 1 to 10 cm in diameter, and exhibited a tendency for necrotic, ulcerative and suppurative changes (Figure 1B). Clinical examination revealed slight emaciation and symmetric enlargement of the superficial lymph nodes (mandibular, cervical, pre-capsular, inguinal). Rectal examination demonstrated slight enlargement of the mesenteric lymph nodes. Haematological examination revealed only leukocytosis $13.4 \times 10^9/l$ (reference range $4.51-12.1 \times 10^9/l$). Serological examination was performed using the ELISA method at the Laboratory of Serological Examinations of Animal Diseases, Regional Veterinary Inspectorate

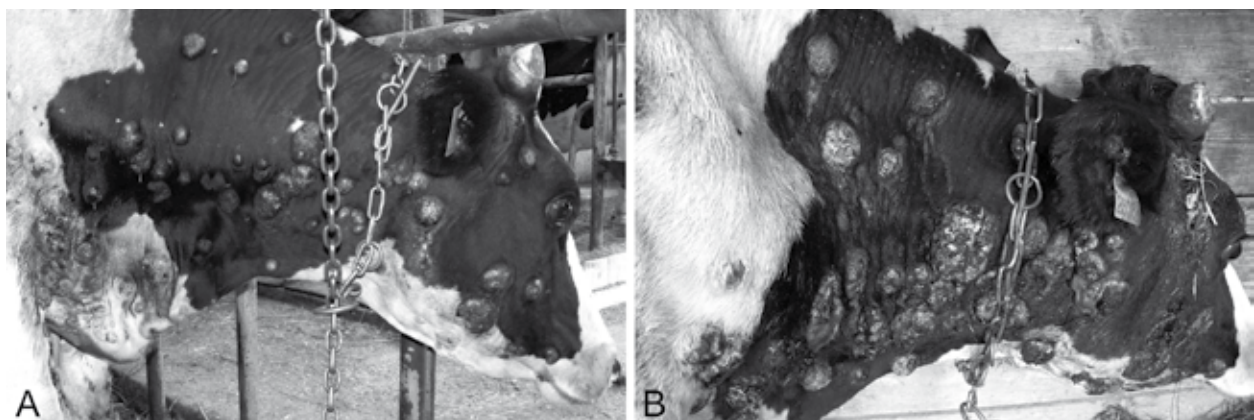


Figure 1. Skin lesions, cow. (A) Hypotrichous and alopecic, cutaneous lesions from 2 cm to 10 cm in diameter, on the neck and head region, one week after the appearance of the first tumour. (B) Mostly alopecic and ulcerated lesions from 8 to 18 cm in diameter, on the neck and head region, four weeks after the appearance of the first tumour

(Olsztyn, Poland). The results excluded bovine leukaemia virus (BLV) infection. Two of the neck tumours were excised by surgical biopsy, fixed in 10% buffered formalin, paraffin embedded, and stained with haematoxylin and eosin (HE). Based on the histopathological examination of the skin biopsies and the resulting poor prognosis, the cow was euthanized one month after the first tumours appeared.

The necropsy examination revealed i.a. enlargement of the superficial, mesenteric and hepatic hilar lymph nodes and spleen. There were no neoplastic lesions in other internal organs. Tissue samples were taken for histopathological and immunohistochemical examination. The samples were fixed in 10% buffered formalin, processed using the routine paraffin technique and histological sections were stained with HE. For the immunohistochemical examination a common immunoperoxidase method was used. The list of primary antibodies is presented in Table 1. The antigen-antibody complexes were visualized using 3,3-diaminobenzidine (DAB) as a chromogen (listed in Table 1). The slides were counterstained with Mayer's haematoxylin. For the negative control, the primary antibody was replaced with mouse IgG2 α (DakoCytomation, Denmark) in the appropriate solution (CD79 α cy, HLA-DR alpha-chain, WC1-N3, Ki67) or omitted (CD3). The normal calf lymph node sections were used as positive controls. The expression levels of Ki67 and MHC class II were evaluated in ten randomly chosen fields of vision

(magnification 600 \times) per slide. The Ki67 labeling index was expressed as the mean percentage of the portion of neoplastic cells that stained positively for Ki67. The mean percentage of cells expressing MHC class II molecules was evaluated separately in lymphoma and the accompanying cells. Ki67- and MHC class II-positive cells were counted using a slide scanner (Panoramic Scanner MIDI, 3DHISTECH, Hungary) and HistoQuant, NuclearQuant and MembraneQuant software (3DHISTECH, Hungary).

Histologically, skin lesions taken *intra vitam* and post-mortem had a similar appearance. Mild epidermal and dense dermal infiltrations of neoplastic cells were observed (Figure 2A). The epidermal infiltration was irregular; the epidermis was thinned and composed of only a few stratum corneum layers and one or two layers of keratinocytes with no basal cells (Figure 2A). Mild to moderate hydropic degeneration and apoptosis was observed in the keratinocytes (Figure 2B). Neoplastic lymphocytes were located predominantly in the basal zone of the epidermis and clustered together, forming Pautrier's microabscesses (Figure 2B). Focally, the epidermis exhibited neutrophilic infiltration mixed with neoplastic lymphocytes, extravasations and cellular debris on the epidermal surface. Mild infiltration of neoplastic cells was noted in the hair follicular epithelium. In the dermis, lymphoid cells had intensively infiltrated the superficial corium, but the deep dermis was less affected. A slight proliferation

Table 1. Primary antibodies used with the particular methods of antigen retrieval and visualization

Primary Antibody	Clone	Optimal dilution	Source	Antigen retrieval	Visualization System	Chromogen
CD3	rabbit anti-human polyclonal	1 : 50	Dako, Denmark	2 \times 3min* TrisEDTA buffer pH=9	Vector Laboratories, USA ^b	DAB ^c
CD79 α cy	mouse anti-human, monoclonal, HM57	1 : 25	Dako, Denmark	4 \times 3min* TrisEDTA buffer pH = 9	Dako, Denmark ^a	DAB ^a
WC1-N3	mouse anti-bovine monoclonal, CACTB32A	1 : 50	VMRD Pullman, USA	4 \times 3min* TrisEDTA buffer pH = 9	Dako, Denmark ^a	DAB ^a
HLA-DR, alpha chain	mouse anti-human monoclonal, TAL.1B5	1 : 20	Dako, Denmark	2 \times 3min* citrate buffer pH = 6	Dako, Denmark ^a	DAB ^a
Ki67	mouse anti-human monoclonal, MIB-1	1 : 75	Dako, Denmark	2 \times 3min* citrate buffer pH = 6	Dako, Denmark ^a	DAB ^a

CD = cluster of differentiation; WC1-N3 = $\gamma\delta$ T-lymphocyte subpopulation; HLA-DR, alpha chain = human leukocyte antigen-DR (major histocompatibility complex MHC class II); Ki67 = nuclear antigen expressed by cells at the G1, S, M and G2 phases of the cell cycle

*antigen retrieval was conducted in a microwave oven, 650W

^aDako EnVision + System-HRP (DAB), DakoCytomation, Denmark

^bImmPress Universal Reagent Anti-Mouse/Rabbit Ig, Vector Laboratories Inc., Burlingame, CA

^cDAB Peroxidase Substrate Kit, 3,3'-diaminobenzidine, Vector Laboratories Inc., Burlingame, CA

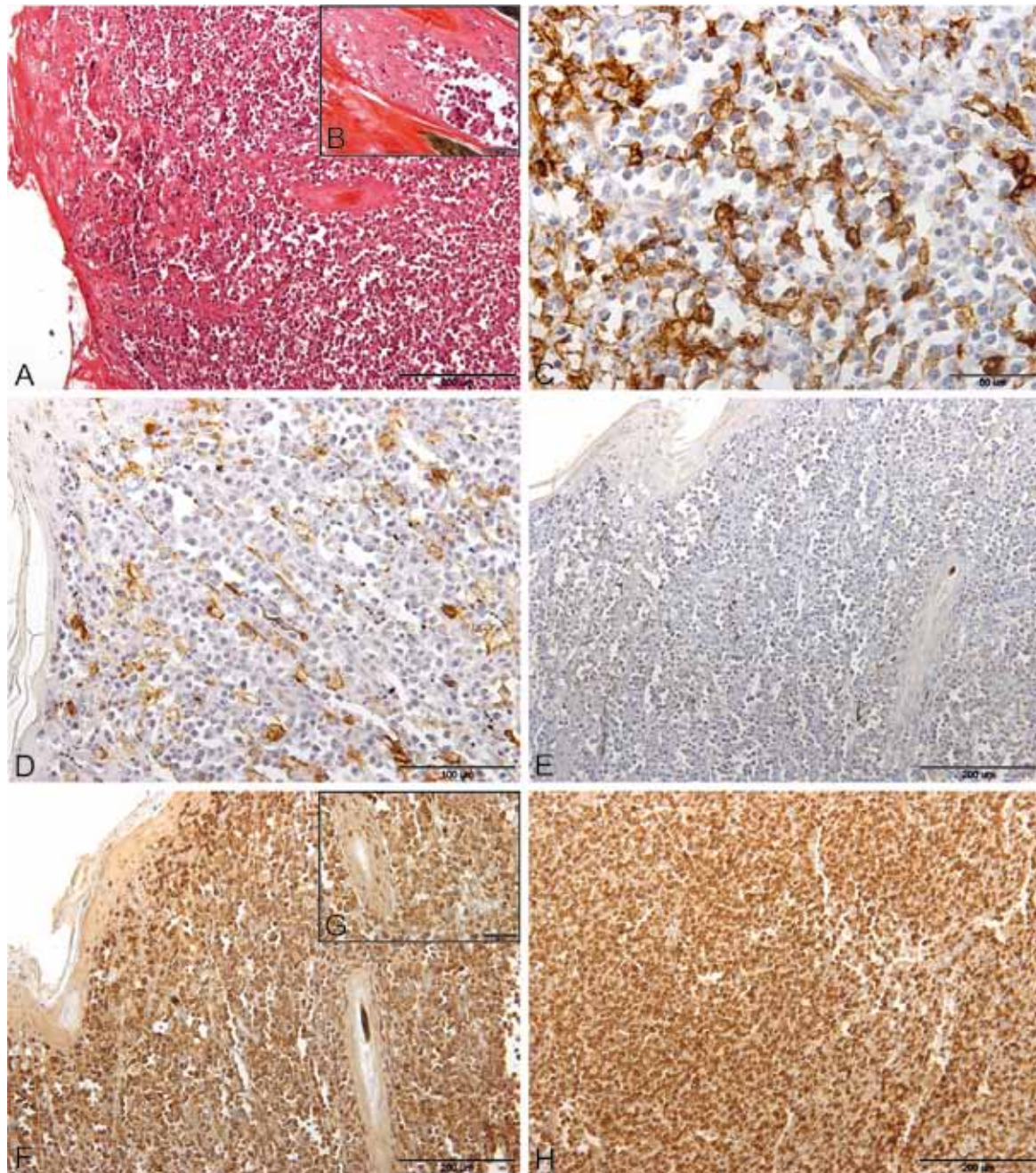


Figure 2. Infiltration of lymphoma cells, cow. (A) Skin, mild epidermal and dense dermal infiltrations of neoplastic cells; haematoxylin and eosin; bar = 200 μ m. (B) Skin with the formation of Pautrier's microabscesses in the epidermis, hydropic degeneration and the apoptosis of keratinocytes; haematoxylin and eosin; bar = 50 μ m. (C) Skin, HLA-DR alpha-chain immunostaining, positive reaction in single lymphoma and accompanying cells; immunohistochemistry, Mayer haematoxylin counterstain; bar = 50 μ m. (D) Skin, CD79 α immunostaining, a negative reaction in lymphoma cells and a positive reaction in single normal B-cells; immunohistochemistry, Mayer haematoxylin counterstain; bar = 100 μ m. (E) Skin, WC1-N3 immunostaining, negative reaction in lymphoma cells; immunohistochemistry, Mayer haematoxylin counterstain; bar = 200 μ m. (F) Skin, CD3 immunostaining, positive reaction in lymphoma cells. immunohistochemistry, Mayer haematoxylin counterstain; bar = 200 μ m. (G) Skin, CD3 immunostaining, positive reaction in lymphoma cells that have infiltrated the dermis and hair epithelium; immunohistochemistry, Mayer haematoxylin counterstain; bar = 50 μ m. (H) Superficial lymph node, CD3 immunostaining, positive reaction in lymphoma cells infiltrating and destroying the lymph node structure; immunohistochemistry, Mayer haematoxylin counterstain; bar = 200 μ m

of the connective tissue and reticular fibres was observed. Neoplastic cells measured 8–11 μm in diameter and were round to polygonal with irregularly round nuclei of medium size, a clumped chromatin pattern, prominent nucleoli and a moderate amount of eosinophilic cytoplasm. The nucleus/cytoplasm ratio was high. The nucleoli varied in number (1–4) and were located close to the nuclear membrane. The neoplastic cells had the appearance of highly immature lymphoid cells. Mitotic figures were frequent (2–18 per high-power magnification fields) and abnormal. The superficial, mesenteric and hepatic hilar lymph nodes displayed a diffuse infiltration of the same neoplastic lymphoid cells as the skin. The superficial lymph nodes were the most affected and their structure was completely obliterated by the neoplastic infiltration (Figure 2H). In the mesenteric lymph nodes, the neoplastic cells had diffusely infiltrated the medulla. This infiltration was associated with the presence of necrosis and extravasation. In the spleen, the red pulp was diffusely infiltrated by neoplastic cells.

Immunohistochemically, the neoplastic cells in all tissue samples were positive for CD3 (Figure 2F–H) and negative for CD79 αcy (Figure 2D) and WC1–N3 (Figure 2E). In the dermis, single CD79 αcy -positive cells were observed between negative lymphoma cells and were interpreted as normal B-cells (Figure 2D). The expression of MHC class II molecules (Figure 2C) was observed in 9.5% to 12.4% of neoplastic cells (mean 10.4%). Positive MHC class II immunoreactivity (Figure 2C) was also observed in 44.3% to 64.7% of accompanying cells with a mean value of 57.26 %. Antigen-presenting cells, i.e., B-cells, activated T-cells, macrophages or dendritic cells, as well as fibroblasts and endothelial and epithelial cells were also present. The same immunoreactivity was observed in the lymph nodes and spleen. The Ki67 expression in the neoplastic cells was highly variable and ranged from 3.4% to 38.5% with a mean value of 15.3%. On the basis of the immunohistochemical, histopathological, and clinical results, a final diagnosis of cutaneous epitheliotropic T-cell lymphoma (T-cell cutaneous form of sporadic bovine leukosis) was made.

DISCUSSION AND CONCLUSIONS

Cutaneous lymphoma in cattle, one of the three forms of sporadic bovine leukosis (SBL), is characterised by primary skin lesions and the occasional

involvement of one or more superficial lymph nodes, often with the secondary infiltration of neoplastic cells to internal organs (Stober 1981; Schweizer et al. 2003). The disease occurs independently of BLV infection, affecting cattle between the ages of two and three years, and concerns only single individuals in the herd (Stober 1981; Zwahlen et al. 1987; Peleteiro et al. 2000; Schweizer et al. 2003; Klinkon and Cerne 2006). This form of SBL may originate from the malignant transformation of either T- or B-lymphocytes. The T-cell type is referred to as epitheliotropic and may be CD4- or CD8-positive, resembling MF or WC1 positive gdT-cell lymphoma. The B-cell type, unrelated to BLV infection, is a rare, non-epitheliotropic type of cutaneous lymphosarcoma that affects cattle (Buczinski et al. 2006; Anjiki et al. 2009). In the present case, the CD3-positive and CD79 αcy -negative reactions in the cytoplasm of neoplastic cells allowed us to identify whether a tumour was of T-cell origin. The lack of WC1–N3 expression allowed us to exclude a gd T-cell origin. The epitheliotropism of lymphoma cells was evident due to infiltration of the basal layer of the epidermis and hair follicular epithelium. The formation of Pautrier's microabscesses in the epithelium, which is not often described in cattle, allowed us to include cases of the MF type of cutaneous lymphoma (Stober 1981; Zwahlen et al. 1987; Peleteiro et al. 2000; Schweizer et al. 2003; Klinkon and Cerne 2006; Vali 2007).

The appearance of skin lesions in the present study was typical for bovine cutaneous lymphoma (Kadota et al. 2001), but their distribution and rapid rate of growth were similar to those observed in only a few cases of T-cell lymphoma (Okada et al. 1989; Peleteiro et al. 2000; Klinkon and Cerne 2006) or dg T-cell lymphoma (Kadota et al. 2001; Sato et al. 2002). Rapid progression of the pathological process corresponded with a high proliferation activity of the lymphoma cells. Typically, the development of skin changes takes a few months (Stober 1981), but information about the case history is often scant (Schweizer et al. 2003). The skin lesions started to appear three months after the first calving, as observed in a few other cases of T-cell cutaneous lymphomas in cattle (Okada et al. 1989; Peleteiro et al. 2000; Sato et al. 2002). In two other described cases, the first tumours started to appear during pregnancy (Peleteiro et al. 2000; Loh 2007). In the literature, there is no information about the possible relation between pregnancy, lactation or the postpartum period and the incidence of cutaneous lymphoma in cattle. Moreover, cutaneous

lymphoma is usually reported in female cattle that are 1–3 years old at precisely the time of the first calving and lactation episode. The underlying cause may be perinatal stress or another environmental or management-associated stressor that affects the immune system. It would be instructive to investigate the immune status of pregnant and lactating cows or herds in which SBL incidents have occurred. However, the characteristic localisation of the first skin lesions, which appeared along lymphatic vessels in the reported study, may suggest an infectious or allergenic agent as the precipitating factor. To date, the exact factor that causes sporadic cutaneous lymphoma in cattle has not yet been identified but the tumour most likely results from a multifactorial and multi-step process as observed in humans (Burg et al. 2006). Additionally, the overexpression of MHC class II observed in accompanying APCs may indicate the presence of tumour-promoting chronic inflammation or the tumour immune surveillance process (Swann and Smyth 2007). The MHC class II-positive reaction in fibroblasts, endothelial cells and epithelial cells in the case described could also represent a response to infection or inflammatory stimulation (Reith et al. 2005). To date, MHC class II expression during T-cell cutaneous lymphoma in cattle and other animals has not been discussed. Epithelial overexpression of this molecule was reported in the abomasum and small intestine in a cow suffering from $\gamma\delta$ T-cell cutaneous lymphoma accompanied by a bacterial infection (Kadota et al. 2001). A positive MHC class II reaction was noted in another case, in a small number of neoplastic cells in a cutaneous $\gamma\delta$ T-cell lymphoma in a cow. This reaction was interpreted as a marker that confirmed the activated cytotoxic $\gamma\delta$ T-cell origin of the neoplastic cells (Sato et al. 2002). Furthermore, the MHC class II expression observed in 10.4% of the neoplastic cells in the presented case corresponded with a poor clinical outcome in human T-cell malignancies (Holling et al. 2004a).

The symmetric enlargement of the superficial lymph nodes on all body regions is often observed during cutaneous T-cell lymphoma in cattle (Stober 1981; Schweizer et al. 2003; Buczinski et al. 2006). Histopathological and immunohistochemical examination in this study confirmed that the superficial and internal lymph nodes were enlarged due to neoplastic T-cell infiltration rather than hyperplasia, as suggested by other authors (Schweizer et al. 2003).

The differential diagnoses of such skin lesions should include erythema multiforme (mature lym-

phocytes), urticaria, dermatophytosis, cutaneous actinobacillosis, warts and chronic lymphocytic leukaemia with cutaneous lesions (Schweizer et al. 2003; Gross et al. 2005; Buczinski et al. 2006). The final diagnosis should be based on the histopathological and immunohistochemical results.

In conclusion, on the basis of clinical, histopathological and immunohistochemical findings, the case described above was classified as a cutaneous epitheliotropic T-cell lymphoma with the involvement of the lymph nodes and spleen that corresponded to MF with dermatopathic lymphadenopathy. Similar cases have been reported in Switzerland (Schweizer et al. 2003; Zwahlen et al. 1987), Portugal (Peleteiro et al. 2000), Japan (Kadota et al. 2001; Sato et al. 2002) Canada (Buczinski et al. 2006; Loh 2007) and Slovenia (Klinkon and Cerne 2006), but this case is the first reported in Poland.

Acknowledgements

We would like to thank Dr. Mirosław Chrzanowski (Large Animal Practice, Orzysz, Poland) for bringing this case to our attention.

REFERENCES

- Anjiki T, Kagawa Y, Ishikawa Y, Kadota K (2009): Immunohistochemical study on cutaneous B cell lymphoma in two cows. *Japan Agricultural Research Quarterly* 41, 33–36.
- Buczinski S, Couture Y, Helie P, Francoz D (2006): Cutaneous T cell Lymphoma in a heifer seropositive for bovine leukosis virus. *Veterinary Record* 158, 665–667.
- Burg G, Kempf W, Cozzio A, Dobbeling U, Freit J, Golling P, Michaelis S, Scharer L, Nestle F, Dummer R (2006): Cutaneous malignant lymphomas: Update 2006. *Journal der Deutschen Dermatologischen Gesellschaft* 4, 914–933.
- Gross TL, Ihrke PJ, Walder EJ, Affolter VK (2005): Lymphocytic tumors. In: Gross TL, Ihrke PJ, Walder EJ, Affolter VK (eds.): *Skin Diseases of the Dog and Cat. Clinical and Histopathologic Diagnosis*, 2nd ed. Blackwell Science, Oxford. 866–893.
- Holling TM, Schooten E, Langerak AW, van den Elsen PJ (2004a): Regulation of MHC class II expression in human T-cell malignancies. *Blood* 103, 1438–1444.
- Holling TM, Schooten E, van den Elsen PJ (2004b): Function and regulation of MHC class II molecules in T-lymphocytes: of mice and men. *Human Immunology* 65, 282–290.

- Kadota K, Wada Y, Ishikawa Y, Shibahara T (2001): gd T-cell lymphoma with tropism for various types of epithelium in a cow. *Journal of Comparative Pathology* 124, 308–313.
- Klinkon M, Cerne M (2006): Cutaneous T-cell lymphoma in heifer with increased serum lactate dehydrogenase activity. *Veterinary Clinical Pathology* 35, 231–234.
- Loh CC (2007): Atypical presentation of cutaneous T-cell lymphosarcoma in a 19-month-old Holstein heifer. *Canadian Veterinary Journal* 48, 309–311.
- Okada K, Yamaguchi A, Ohshima K, Naumakunai S, Itoh H, Seimiya Y, Koyama H (1989): Spontaneous regression of bovine cutaneous leukosis. *Veterinary Pathology* 26, 136–143.
- Peleteiro MC, Pinto C, Correia JJ, Silva JF, Branco S (2000): Two cases of cutaneous T cell lymphoma in Fresian cows in the Azores. *Veterinary Dermatology* 11, 299–304.
- Reith W, LeibundGut-Landmann S, Waldburger JM (2005): Regulation of MHC class II gene expression by the class II transactivator. *Nature Reviews Immunology* 5, 793–806.
- Sato K, Shibahara T, Kadota K (2002): dg T-cell lymphoma in a cow. *Australian Veterinary Journal* 80, 705–707.
- Schweizer G, Hilbe M, Braun U (2003): Clinical, haematological, immunohistochemical and pathological findings in 10 cattle with cutaneous lymphoma. *Veterinary Record* 153, 525–528.
- Stober M (1981): The clinical picture of the enzootic and sporadic forms of bovine leukosis. *Bovine Practitioner* 16, 119–129.
- Swann JB, Smyth MJ (2007): Immune surveillance of tumors. *Journal Clinical Investigation* 117, 1137–1146.
- Valli E (2007): Haematopoietic system. In: Maxie MG (ed.): *Jubb, Kennedy and Palmer's Pathology of Domestic Animals*. 3rd ed. Vol. 3. Elsevier Saunders, Philadelphia. 177–203.
- Willemze R, Dreyling M (2010): Primary cutaneous lymphomas: ESMO Clinical practice guidelines for diagnosis, treatment and follow-up. *Annals of Oncology* 21 (Suppl 5), 177–180.
- Zwahlen RD, Tontis A, Schneider A (1987): Cutaneous lymphosarcoma of helper/inducer T-cell origin in a calf. *Veterinary Pathology* 24, 504–508.

Received: 2012–04–20

Accepted after corrections: 2012–05–11

Corresponding Author:

Iwona Otrocka-Domagala, Warmia and Mazury University in Olsztyn, Veterinary Medicine Faculty, Oczapowskiego Street 13 bl. D, 10-719 Olsztyn, Poland
Tel. +48 89 5246144; Fax +48 89 5233458, E-mail: i.otrocka-domagala@uwm.edu.pl
