

Successful response to imatinib in two dogs with inoperable grade III infiltrating mast cell tumours: a case report

J.H. KIM¹, H.J. KIM¹, D.H. KIM², J.H. YIM², S.J. LEE², K.H. PARK², H.Y. YOON²

¹Konkuk University Veterinary Medical Teaching Hospital, Seoul, Republic of Korea

²College of Veterinary Medicine, Konkuk University, Seoul, Republic of Korea

ABSTRACT: Two dogs were presented owing to sudden rapid growth of cutaneous masses greater than 10 cm on the neck and axillary region, respectively. Based on history and results of physical examinations, blood work, fine needle aspiration, histopathological examination, and computed tomography, inoperable grade III infiltrating mast cell tumours were diagnosed. After the initiation of imatinib treatment, the masses markedly shrank and became undetectable within 10 days in both dogs, although none of the tumour specimens showed evidence of mutations in sequencing of *c-kit* exons 8 and 11. These results suggest that imatinib could be a therapeutic option in patients with surgically inoperable canine mast cell tumours, even those that are histopathologically high grade without *c-kit* exon 8 or 11 mutations.

Keywords: canine; KIT; oncogene; target therapy; tyrosine kinase inhibitor

Mast cell tumours (MCTs) are one of the most common cutaneous neoplasms in dogs and are often aggressive (London and Seguin 2003; Yamada et al. 2011). In cases of aggressive MCTs, widespread dissemination of the tumour or infiltration to surrounding organs could occur, rendering the tumour completely surgically non-resectable. In the past, in such inoperable cases, chemotherapy and radiotherapy were the possible therapeutic options. However, unsatisfactory success rates and relatively high toxicity rates of systemic chemotherapy, as well as difficulties in access with radiotherapy, justify the exploration of new treatment options for MCT patients (Cooper et al. 2009; Yamada et al. 2011).

Recently, tyrosine kinase inhibitors (TKIs) have begun to be used for canine MCTs as a novel targeted therapy (Hahn et al. 2008; Isotani et al. 2008; London et al. 2009; Yamada et al. 2011). Many previous studies have demonstrated that response to imatinib, which is a TKI, can be correlated with the presence of mutations in *c-kit* oncogene exons 8 and 11 found in canine MCT (Kobayashi et al. 2012; Nakano et al. 2014). Furthermore, these mutations

occur in higher-grade tumours and their presence can be used to provide evidence of poor prognosis such as recurrence and metastasis (Downing et al. 2002; Zemke et al. 2002). In the present report, however, treatment with imatinib successfully decreased the size of inoperable grade III infiltrating MCT masses in both of the cases even in the absence of mutations in exons 8 and 11 of *c-kit*.

In this report, we describe the clinical course and nucleotide sequencing of *c-kit* exon 8 and 11 using fine needle aspiration (FNA) samples of inoperative high-grade MCTs in two dogs, and the successful treatment of the tumours with imatinib.

Case description

Dog 1 was a 6-year-old, 39 kg castrated male Golden Retriever presented for acute growth of neck masses over the preceding 10 days. On initial physical examination, dermal masses greater than 10 cm in diameter in the dorsal and ventral cervical region were detected. These masses were firm

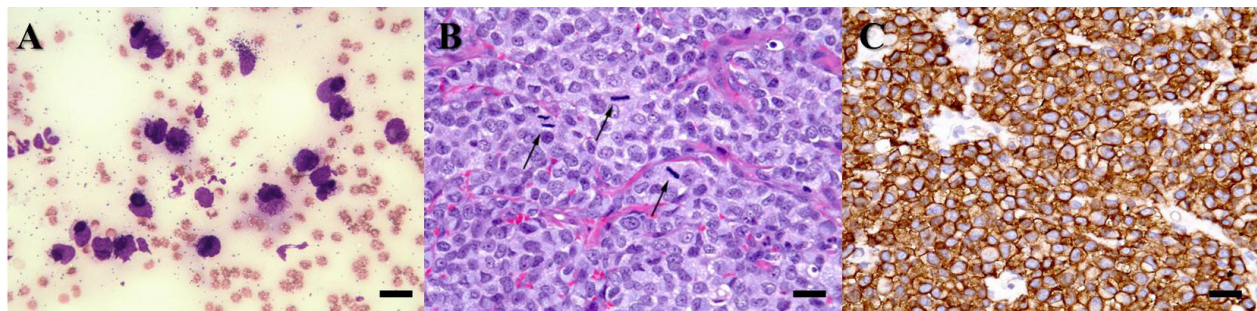


Figure 1. (A) Fine needle aspiration of the cervical masses detected in this dog reveals numerous degranulated round cells with fine granules and with an increased nuclear-to-cytoplasmic ratio, prominent nucleoli, and anisokaryosis indicating mast cell tumour (MCT) (Diff-Quik, $\times 400$, scale bar = 20 μm). (B) Histopathology of the masses shows moderate levels of degranulated mast cells with fine cytoplasmic granules having malignant features including large dysmorphic nuclei with anisokaryosis and prominent nucleoli. Numerous mitotic figures are seen (arrows). Haematoxylin and eosin staining, $\times 400$, scale bar = 20 μm . (C) Immunohistochemistry (IHC) shows that tumour cells are immunolabelled with KIT (CD117), which shows a membrane and diffuse cytoplasmic staining pattern. Diffuse cytoplasmic staining, $\times 400$, scale bar = 20 μm

and partially connected to each other. A complete blood count (CBC) and serum biochemical profile showed no remarkable findings. Fine needle aspiration (FNA) biopsy performed on the masses demonstrated numerous degranulated round cells with fine granules and with an increased nuclear-to-cytoplasmic ratio, prominent nucleoli, and anisokaryosis, indicating MCT (Figure 1A). In addition, large numbers of mast cells were also found in aspirated samples from the left submandibular lymph nodes in this dog, suggesting metastasis. However, mast cells were not identified on buffy coat analysis. Survey radiographs revealed an asymmetrical soft-tissue density mass in the left cervical region without bone lysis (Figure 2A). To determine the detailed anatomical location of

the masses, computed tomography (CT) was performed. CT images obtained using a LightSpeed Plus apparatus (GE Medical Systems, Waukesha, WI, USA) revealed that the homogeneous mass in the cervical region had infiltrated adjacent muscle and was moderately contrast-enhanced (Figure 3). Due to infiltration to surrounding muscles, surgically complete excision of the mass could not be performed, but incisional biopsies were obtained. The biopsy samples of the tumour revealed incomplete margins and aggressive histomorphological features including an occasionally high mitotic index ($> 5/\text{oil immersion field}$), moderate degranulation with fine granules, and dysmorphic nuclei with anisokaryosis (Figure 1B). These malignant tumour cells were densely proliferating and showed

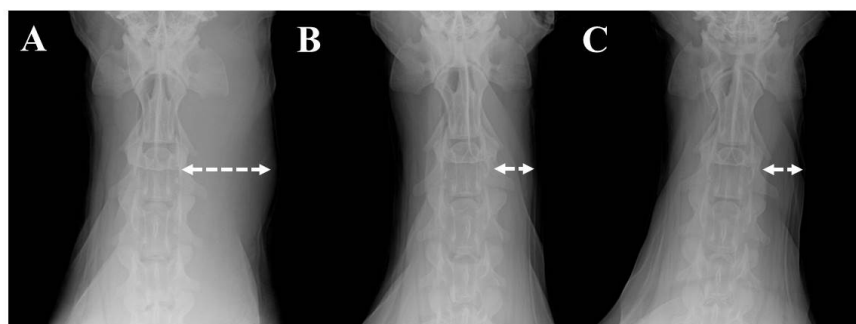


Figure 2. Clinical course of Dog 1 as evaluated by changes in tumour size on X-rays. The patient was treated with imatinib and radiographic examination showed gradual regression of the left cervical mass (dotted arrows). (A) On presentation day, the soft-tissue density mass in the left cervical region was asymmetrical. (B) In Week 1, the cervical mass had become undetectable after the initiation of imatinib therapy. (C) In Week 10, the mass was still undetectable and regression was sustained until first relapse at Week 25. The dog lived for 37 weeks after starting imatinib administration

doi: 10.17221/87/2016-VETMED

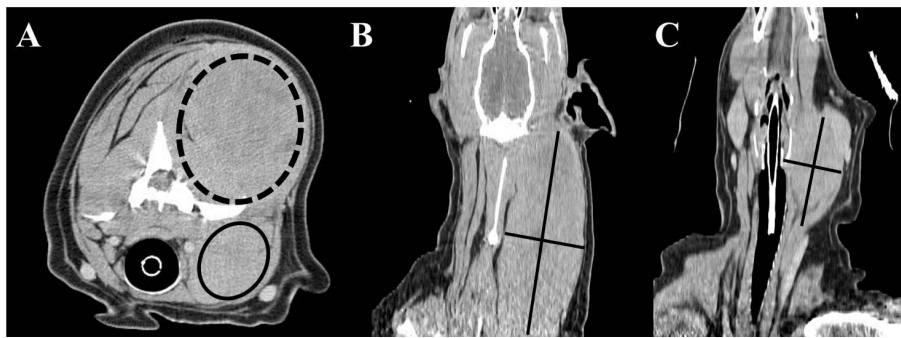


Figure 3. (A) Transverse view of cervical region masses on computed tomographic examination. Note poorly demarcated and partially connected dorsal (dotted circle) and ventral (circle) masses. (B) Dorsal view of cervical dorsal region shows a moderately contrast-enhanced large tumour mass in the left cervical region homogeneous with adjacent muscle; size: 8.7×18 cm. (C) Dorsal view of the cervical ventral region shows a moderately contrast-enhanced homogeneous tumour mass medial to the mandibular salivary gland; size: 4.7×6.4 cm

invasion of dermis and muscle layers. Additionally, immunohistochemistry (IHC) for KIT (CD117) was performed, and the results revealed strong positive cell membrane staining, which was consistent with undifferentiated mast cells (Figure 1C). Histopathological evaluation demonstrated incompletely excised grade III MCTs with strong positive IHC results for KIT. To identify specific mutations, tumour cells were obtained from FNA and polymerase chain reaction (PCR) was performed following the consent of the dog's owner. Tumour samples from FNA were washed three times with phosphate buffered saline (pH 7.2, Difco Laboratories Inc., Detroit, MI, USA), and genomic DNA was isolated using the DNeasy Blood & Tissue Kit (Qiagen, Valencia, CA, USA) according to the manufacturer's protocol and eluted in 50 μ l of Tris-EDTA buffer. To screen for mutations in *c-kit* ex-

ons 8 and 11, the following primer sets developed by Nakano et al. (2014) were used for amplifying *c-kit* exons 8 and 11: for exon 8, the forward primer was 5'-AGCCTTG GTGAGGTGTTCCA-3' and the reverse primer was 5'-CTACCCTGCTGTCCTTCCCT-3'; for exon 11, the forward primer was 5'-CATTTGTTCTCTACCCTAAGTGCTA-3' and the reverse primer was 5'-GTTCCCTAAAGT-CATTGTTACACG-3'. The amplicons of exons 8 and 11 were 228 and 227 base pairs, respectively. Each PCR amplification reaction was performed using 20 μ l reaction mixtures consisting of 10 μ l of HotStart PCR premix (iMOD, SNC, Seoul, Korea) and 0.5 μ M concentrations of primers. Thermocycling conditions were as follows: 95 °C for 120 s, 35 cycles of 94 °C for 30 s, 60 °C for 30 s, and 72 °C for 30 s. Amplified products were visualised by electrophoresis on 2% agarose

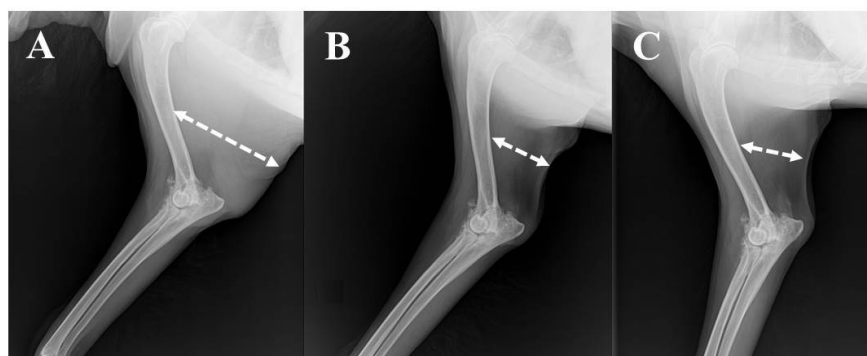


Figure 4. Clinical course of Dog 2 as evaluated by changes in tumour size on X-rays. The patient was treated with imatinib and radiographic examination showed gradual regression of the right axillary mass (dotted arrows). (A) On presentation day, a soft-tissue density mass in the right axillary region was visible. (B) On Day 10, the right axillary mass had become undetectable. (C) On Day 30, the mass was still undetectable and regression was sustained until first relapse at Week 10, and the dog lived for 20 weeks after starting imatinib administration

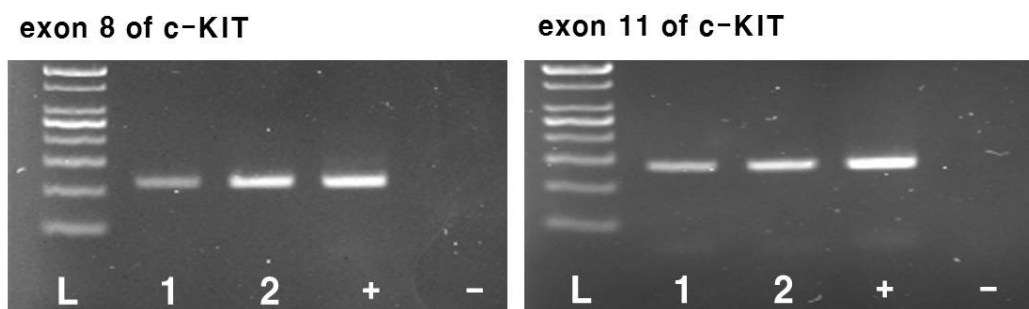


Figure 5. Electrophoresis of polymerase chain reaction (PCR) products of exon 8 and 11 of *c-kit* from mast cell tumour (MCT) samples from Dogs 1 and 2

L = 100 base pair (bp) ladder; 1 = Dog 1; 2 = Dog 2; + = positive PCR control (healthy dog); – = negative PCR control (water)

gels (Figure 5). Finally, DNA fragments were excised for DNA purification. DNA was purified using the QIAEX II Gel Extraction Kit (Qiagen) according to the manufacturer's protocol. The extracted DNA fragments were sequenced using ABI BigDye v3.1 terminator sequencing chemistry according to the manufacturer's instructions for a BigDye® Terminator v3.1 Cycle sequencing kit (Applied Biosystems, Foster City, CA, USA) in an Applied Biosystems 3730xl DNA Analyzer at Cosmo Genetech, Korea. For both exons 8 and 11, DNA from this dog provided a clear single banding pattern. Additionally, in sequence analysis of the bands, no mutations were found in either exon 8 or 11 in this dog.

Based on the history and results of physical, cytological, and histopathological examinations, as well as the PCR results, high-grade inoperative MCT was diagnosed and chemotherapy was recommended as an initial treatment. However, chemotherapeutic drugs were not selected due to the owner's request. Finally, the dog was treated orally with imatinib (Gleevec®; Novartis, Basel, Switzerland), which is the only available tyrosine kinase inhibitor in our hospital, at a dose of 10 mg/kg daily for 10 weeks. In the first three weeks, prednisolone (Solondo®; Yahan Co., Seoul, Korea; from 1 to 0.5 mg/kg orally once a day), chlorpheniramine (Peniramin®; Yahan Co., Seoul, Korea; 3 mg/kg orally once a day), and famotidine (Famotidine®; Hanmi Pharm., Seoul, Korea; 0.5 mg/kg orally twice a day) were given concomitantly to the dog to decrease the inflammation associated with the tumour cells and protect against the effects of histamine released from the tumour cells, respectively. The cervical masses shrank rapidly and were observed to have disappeared completely one week after the start of oral medication (Figure 2B). During the period of treatment with imatinib, no

abnormalities in haematological test results, including CBC and serum biochemistry, or physical examination findings were noted in the dog. Ten weeks after presentation, the patient was still alive with no detectable masses (Figure 2C), and all medications were terminated due to good response and the owner's financial concerns. From the time of presentation, there was no recurrence for 25 weeks. However, 15 weeks after discontinuation of the medication, the cervical mass recurred. At that time, the imatinib was re-administered and the mass regressed and was again undetectable within two weeks. The medication was continued for 10 weeks in this patient. Thereafter, the dog remained healthy for 22 weeks with no recurrences and the dog lived for 37 weeks (nine months) after the initiation of imatinib. However, the patient was subsequently euthanised due to acute pain of unknown origin with hind limb paralysis at a local animal hospital. Unfortunately, necropsy could not be performed due to the owner's refusal.

Dog 2 was a 13-year-old, 29 kg castrated male Golden Retriever referred with a history of recurrence of a previously excised cutaneous MCT with infiltration to adjacent muscle in the right axillary region that had developed over three months. During the previous surgery, the skin, fat, subcutaneous tissue, and fascia had been removed along a 5 cm margin along the tumour edge. Additionally, the deep pectoral muscle adjacent to the mass was partially resected. The surgically excised tumour was histopathologically diagnosed as an incompletely resected infiltrating grade III MCT. No further therapy had been given at that time due to the owner's request. At presentation, a newly formed right axillary mass greater than 10 cm in diameter was observed. CBC and serum biochemical profile showed no remarkable findings with the exception of mild normocytic and normochromic anaemia

doi: 10.17221/87/2016-VETMED

(red blood cell count $5.31 \times 10^6/\mu\text{l}$, reference interval $5.5\text{--}8.5 \times 10^6/\mu\text{l}$; haemoglobin concentration 124 g/l, reference interval 130–200 g/l; HCT 34.1%, reference interval 40–55%). Additionally, on buffy coat analysis, mast cells were not identified. Survey radiographs revealed an asymmetrical soft-tissue density mass in the right axillary-to-humerus region without evidence of bone lysis (Figure 4A). Cells in the tumour aspirate were almost entirely composed of mast cells and moderately to highly granulated round cells. An additional FNA sample was obtained for PCR analysis of *c-kit* mutations. DNA preparation and sequencing of *c-kit* exons 8 and 11 was performed in the same manner as for Dog 1. As in Dog 1, no mutations were found in either exon 8 or 11 in this dog (Figure 5). Ultimately, this dog was diagnosed with recurrent inoperable grade III infiltrating MCT.

Based on the diagnosis, the patient was treated with imatinib. Additionally, we administered prednisolone, chlorpheniramine, and famotidine for palliative reasons, as described in the case of Dog 1. After the initiation of medication, the volume of the mass rapidly shrank and became undetectable within 10 days (Figure 4B), and regression was sustained on follow-up at Day 30 (Figure 4C). Although imatinib was administered without a break, recurrence of the mass in the axillary region was observed, and splenic metastasis occurred in Week 10. At this point, chemotherapy was suggested, but the owner declined both chemotherapy and any further examination due to the poor prognosis. However, the therapy with imatinib was continued and the patient lived an additional 10 weeks. On Week 20 (5 months), the dog died at home. An autopsy could not be performed due to the owner's refusal.

DISCUSSION AND CONCLUSIONS

In canine MCT, the presence of molecular alterations in the *c-kit* proto-oncogene is a well-studied potential prognostic factor (Zavodovskaya et al. 2004). The protein product of *c-kit* is the receptor tyrosine kinase (KIT), which is expressed on mast cells and has important roles in mast cell activation, differentiation, proliferation, and survival (Galli and Kitamura 1987; Galli et al. 1994). Activating mutations in *c-kit* have been reported in both human and canine cancers (Nagata et al. 1997; London et

al. 1999; Ma et al. 1999). These mutations make KIT active without ligand binding, leading to constitutive or amplified KIT signalling, which finally results in abnormal proliferation and survival of cells expressing these mutations (London et al. 1999; Ma et al. 1999; Pryer et al. 2003). In canine MCT, many previous studies have identified specific mutations in exons 8 and 11 of the *c-kit* oncogene and demonstrated that these mutations occur in higher-grade tumours and correlate with recurrence and metastasis (Downing et al. 2002; Zemke et al. 2002).

For the control of MCTs carrying *c-kit* exon 8 and 11 mutations, several previous studies have shown that TKIs can be effective, and imatinib has recently begun to be utilised for canine MCT as a novel targeted therapy (Kobayashi et al. 2012; Nakano et al. 2014). Imatinib is a commercially available drug targeting tyrosine kinases, and it inhibits downstream signalling of KIT by competing with adenosine triphosphate (ATP) for the ATP binding site (Buchdunger et al. 2002). It has potent therapeutic activity against canine MCT driven by constitutively phosphorylated protein tyrosine kinases, an outcome resulting from mutation of the corresponding *c-kit* gene (London et al. 1999; Ma et al. 1999; Liao et al. 2002). Mutations consisting of internal tandem duplication (ITD) within *c-kit* exons 8 and 11, which causes ligand-independent phosphorylation of KIT, have been frequently found in high-grade MCT in dogs (London et al. 1999; Downing et al. 2002; Zemke et al. 2002; Webster et al. 2006; Kobayashi et al. 2012). It has been reported that canine MCT with these mutations in the exon 8 and exon 11 regions regressed after treatment with imatinib in xenografted severe combined immunodeficiency (SCID) mice and dogs with spontaneous MCT (Kobie et al. 2007; Kobayashi et al. 2012; Nakano et al. 2014). Moreover, other studies reported that several TKIs with different chemical structures from imatinib induced objective tumour regression in canine MCTs with these mutations (London et al. 2003; Hahn et al. 2008; London et al. 2009). However, several studies reported that clinical activity of imatinib against MCT could not be predicted based on the presence of mutations in exon 8 or 11 of *c-kit* (Isotani et al. 2008; Bonkobara 2015) as in the cases described here.

During the therapy with imatinib, glucocorticoid was concomitantly used in the initial three weeks with tapering. Therefore, the initial successful response in the present study could be partially

attributed to the concurrent glucocorticoid administration. In particular, the local anti-inflammatory effects of glucocorticoid can partially mask tumour recurrence. However, no tumour progression was observed over a period of seven weeks after termination of the use of glucocorticoid in both cases. In the present cases, we prescribed the glucocorticoid for palliative reasons only, and we consider that imatinib played a crucial role in the clinical responses in these dogs, as has also been shown in previous studies (Isotani et al. 2004; Yamada et al. 2011).

In Dog 2, although we continued treatment with imatinib, the MCT progressed after Week 10 of treatment. Insensitivity to imatinib after an initial favourable response has been described in human cancer, in which mutant KIT is a central pathogenetic feature as in canine MCT (Antonescu et al. 2005). That report demonstrated reactivation of KIT by emergence of a second-site mutation in *c-kit*, which caused the acquisition of resistance in tumours that initially responded to imatinib. Unfortunately, we were not able to examine the entire nucleotide sequence of *c-kit* after the occurrence of insensitivity to imatinib therapy in this dog. Furthermore, other mechanisms such as decreased drug influx pumps, excessive binding of imatinib to interfering plasma proteins, overexpressed multidrug-resistance P-glycoprotein, or other signalling pathways might underlie the acquired insensitivity to imatinib in this case. In the present study, imatinib appeared to be well tolerated and no adverse effects including hepatotoxicity were noted in either of the dogs during treatment with imatinib, although hepatotoxicity at a relatively higher dose was reported in a study regarding the toxicity of imatinib in dogs (Druker and Lydon 2000).

On the basis of the successful responses of MCT to imatinib in the cases described here, we suggest that the tumour cells possessed abnormally activated KIT resulting from mutations other than those in exons 8 and 11 of *c-kit*, which are commonly reported in canine MCT. Furthermore, in Dog 1, the result of IHC for KIT was strongly positive, supporting the likelihood of aberrantly activated KIT. Considering the recent reports that canine MCT can also be related to other mutations in exons 9, 13, and 17 of *c-kit*, and the platelet-derived growth factor receptor alpha (PDGFRA) gene, we suggest that future studies should focus on analysis of these

genes as well as exons 8 and 11 of *c-kit* (Isotani et al. 2008; Gregory-Bryson et al. 2010).

In conclusion, we suggest that imatinib should be considered as a therapeutic strategy in inoperable canine MCTs, even those without *c-kit* exon 8 or 11 mutations, and that the response to imatinib should not be predicted solely based on the presence or absence of these mutations. Furthermore, additional studies are warranted to examine the entire nucleotide sequence of *c-kit* DNA samples before and after imatinib therapy to detect other mutations inducing tumorigenesis and acquired second-site mutations inducing resistance in dogs with MCT.

Acknowledgement

This study was supported by Konkuk University Veterinary Medical Teaching Hospital, South Korea.

REFERENCES

- Antonescu CR, Besmer P, Guo T, Arkun K, Hom G, Koryotowski B, Leversha MA, Jeffrey PD, Desantis D, Singer S, Brennan MF, Maki RG, DeMatteo RP (2005): Acquired resistance to imatinib in gastrointestinal stromal tumor occurs through secondary gene mutation. *Clinical Cancer Research* 11, 4182–4190.
- Bonkobara M (2015): Dysregulation of tyrosine kinases and use of imatinib in small animal practice. *Veterinary Journal* 205, 180–188.
- Buchdunger E, O'Reilley T, Wood J (2002): Pharmacology of imatinib (STI571). *European Journal of Cancer* 38, S28–S36.
- Cooper M, Tsai X, Bennett P (2009): Combination CCNU and vinblastine chemotherapy for canine mast cell tumours: 57 cases. *Veterinary and Comparative Oncology* 7, 196–206.
- Downing S, Chien MB, Kass PH, Moore PF, London CA (2002): Prevalence and importance of internal tandem duplications in exons 11 and 12 of *c-kit* in mast cell tumors of dogs. *American Journal of Veterinary Research* 63, 1718–1723.
- Druker BJ, Lydon NB (2000): Lessons learned from the development of an abl tyrosine kinase inhibitor for chronic myelogenous leukemia. *The Journal of Clinical Investigation* 105, 3–7.
- Galli SJ, Kitamura Y (1987): Genetically mast-cell-deficient W/W^v and Sl/Sl^d mice. Their value for the analysis of the roles of mast cells in biologic responses in vivo. *The American Journal of Pathology* 127, 191–198.
- Galli SJ, Zsebo KM, Geissler EN (1994): The kit ligand, stem cell factor. *Advances in Immunology* 55, 1–96.

doi: 10.17221/87/2016-VETMED

- Gregory-Bryson E, Bartlett E, Kiupel M, Hayes S, Yuzbasiyan-Gurkan V (2010): Canine and human gastrointestinal stromal tumors display similar mutations in c-KIT exon 11. *BMC Cancer* 10, 559.
- Hahn KA, Ogilvie G, Rusk T, Devauchelle P, Leblanc A, Legendre A, Powers B, Leventhal PS, Kinet JP, Palmerini F, Dubreuil P, Moussy A, Hermine O (2008): Masitinib is safe and effective for the treatment of canine mast cell tumors. *Journal of Veterinary Internal Medicine* 22, 1301–1309.
- Isotani M, Ishida N, Tominaga M, Tamura K, Yagihara H, Ochi S, Kato R, Kobayashi T, Fujita M, Fujino Y, Setoguchi A, Ono K, Washizu T, Bonkobara M (2008): Effect of tyrosine kinase inhibition by imatinib mesylate on mast cell tumors in dogs. *Journal of Veterinary Internal Medicine* 22, 985–988.
- Kobayashi M, Sugisaki O, Ishii N, Yamada O, Ito K, Kuroki S, Sasaki Y, Ono K, Washizu T, Bonkobara M (2012): Canine intestinal mast cell tumor with c-kit exon 8 mutation responsive to imatinib therapy. *Veterinary Journal* 193, 264–267.
- Kobie K, Kawabata M, Hioki K, Tanaka A, Matsuda H, Mori T, Maruo K (2007): The tyrosine kinase inhibitor imatinib [STI571] induces regression of xenografted canine mast cell tumors in SCID mice. *Research in Veterinary Science* 82, 239–241.
- Liao AT, Chien MB, Shenoy N, Mendel DB, McMahon G, Cherrington JM, London CA (2002): Inhibition of constitutively active forms of mutant kit by multitargeted indolinone tyrosine kinase inhibitors. *Blood* 100, 585–593.
- London CA, Seguin B (2003): Mast cell tumors in the dog. *The Veterinary Clinics of North America: Small Animal Practice* 33, 473–489.
- London CA, Galli SJ, Yuuki T, Hu ZQ, Helfand SC, Geissler EN (1999): Spontaneous canine mast cell tumors express tandem duplications in the proto-oncogene c-kit. *Experimental Hematology* 27, 689–697.
- London CA, Hannah AL, Zadovskaya R, Chien MB, Kollias-Baker C, Rosenberg M, Downing S, Post G, Boucher J, Shenoy N, Mendel DB, McMahon G, Cherrington JM (2003): Phase I dose-escalating study of SU11654, a small molecule receptor tyrosine kinase inhibitor, in dogs with spontaneous malignancies. *Clinical Cancer Research* 9, 2755–2768.
- London CA, Malpas PB, Wood-Follis SL, Boucher JF, Rusk AW, Rosenberg MP, Henry CJ, Mitchener KL, Klein MK, Hintermeister JG, Bergman PJ, Couto GC, Mauldin GN, Michels GM (2009): Multi-center, placebo-controlled, double-blind, randomized study of oral toceranib phosphate (SU11654), a receptor tyrosine kinase inhibitor, for the treatment of dogs with recurrent (either local or distant) mast cell tumor following surgical excision. *Clinical Cancer Research* 15, 3856–3865.
- Ma Y, Longley BJ, Wang X, Blount JL, Langley K, Caughey GH (1999): Clustering of activating mutations in c-KIT's juxtamembrane coding region in canine mast cell neoplasms. *The Journal of Investigative Dermatology* 112, 165–170.
- Nagata H, Okada T, Worobec A, Semere T, Metcalfe D (1997): C-kit mutation in a population of patients with mastocytosis. *International Archives of Allergy and Immunology* 113, 184–186.
- Nakano Y, Kobayashi T, Oshima F, Fukazawa E, Yamagami T, Shiraishi Y, Takanosu M (2014): Imatinib responsiveness in canine mast cell tumors carrying novel mutations of c-KIT exon 11. *The Journal of Veterinary Medical Science* 76, 545–548.
- Pryer NK, Lee LB, Zadovskaya R, Yu X, Sukbuntherng J, Cherrington JM, London CA. (2003): Proof of target for SU11654 inhibition of KIT phosphorylation in canine mast cell tumors. *Clinical Cancer Research* 9, 5729–5734.
- Webster JD, Yuzbasiyan-Gurkan V, Kaneene JB, Miller R, Resau JH, Kiupel M (2006): The role of c-KIT in tumorigenesis: evaluation in canine cutaneous mast cell tumors. *Neoplasia* 8, 104–111.
- Yamada O, Kobayashi M, Sugisaki O, Ishii N, Ito K, Kuroki S, Sasaki Y, Isotani M, Ono K, Washizu T, Bonkobara M (2011): Imatinib elicited a favorable response in a dog with a mast cell tumor carrying a c-kit c.1523A>T mutation via suppression of constitutive KIT activation. *Veterinary Immunology and Immunopathology* 142, 101–106.
- Zadovskaya R, Chien MB, London CA (2004): Use of kit internal tandem duplications to establish mast cell tumor clonality in 2 dogs. *Journal of Veterinary Internal Medicine* 18, 915–917.
- Zemke D, Yamini B, Yuzbasiyan-Gurkan V (2002): Mutations in the juxtamembrane domain of c-KIT are associated with higher grade mast cell tumors in dogs. *Veterinary Pathology* 39, 529–535.

Received: 2016–05–18

Accepted after corrections: 2016–06–26

Corresponding Author:

Hun-Young Yoon, Konkuk University, College of Veterinary Medicine, Department of Veterinary Surgery,
20 Neungdong-ro, Gwangjin-gu, Seoul, 143-701, Republic of Korea
E-mail: yoonh@konkuk.ac.kr