

Efficacy of *Chromolaena odorata* leaf extracts for the healing of rat excision wounds

K. VIJAYARAGHAVAN¹, J. RAJKUMAR², M.A. SEYED^{3*}

¹Agni College of Technology, Chennai, India

²Rajalakshmi Engineering College, Chennai, India

³University of Tabuk, Tabuk, Kingdom of Saudi Arabia

*Corresponding author: sdmdali.ali@gmail.com

ABSTRACT: Injury to the soft tissues is followed by wound healing, which consists of four stages: haemostasis, inflammation, proliferation and remodelling. *Chromolaena odorata* is a weed that is traditionally used for the treatment of various ailments in humans and animals. The present study was aimed at exploring the wound healing potential of aqueous and ethanolic extracts of *C. odorata* in a rat excision wound model. This investigation involved phytochemical screening and *in vitro* analyses of various parameters such as antioxidant activity, lipid peroxide inhibitory activity and the effects of extracts on contraction and epithelialisation of the rat excision wounds. The phytochemical screening of both ethanolic and aqueous extracts showed that they were rich in secondary metabolites such as alkaloids, flavonoids, tannins, saponins, terpenoids, anthraquinones, cardiac glycosides and carbohydrates. The aqueous extract showed high antioxidant and lipid peroxide inhibitory activity, while the ethanolic extract showed high total phenol content and hydrogen peroxide inhibitory activity at concentrations of 50, 100 and 250 µg/ml. Our results also indicate that the most effective concentration of the *C. odorata* extract for excision wound healing was 5.0% (w/w). *C. odorata*-treated groups exhibited a faster reduction in wound area compared to control and Betadine-treated groups. In addition, the topical application of *C. odorata* extract increased collagen synthesis and its stabilisation at the wound site, as evidenced by the increase in hydroxyproline and hexosamine levels and expression of collagen. The present investigation demonstrates that aqueous and ethanolic extracts of *C. odorata* of varying concentrations promote an accelerated wound healing process and might represent a novel healing agent. Our findings are of potential clinical relevance and might be highly beneficial for drug discovery and development in the area of both human and veterinary medicine.

Keywords: Betadine; hydroxyproline; hexosamine; collagen; siam weed; traditional medicine; phytochemicals; antioxidant; invasive species; ornamental plant

Wounds are physical injuries to the skin that take various forms including lacerated wounds, bruises, burns, etc. Based on the physiology of wound healing and its various phases, wounds can be classified as open or closed wounds, and acute or chronic wounds (Meenakshi et al. 2006; Nagori and Solanki 2011). The proper healing of wounds is essential for restoration of disrupted anatomical integrity and altered function of the affected area (Edlich et al. 2005). Healing is a complex and difficult process initiated in response to an injury that serves to restore

the function and integrity of the damaged tissues (Wietecha and DiPietro 2013). Chronic wounds, in particular, are a major concern for animals, humans and clinicians, as they affect a large number of patients, leading to a significant reduction in their quality of life (Hostetler et al. 2006; Belmont et al. 2010). Wound healing is a normal biological process in the body and is achieved through four precisely and highly programmed phases, i.e., haemostasis, inflammation, proliferation and remodelling. Wound healing also involves a variety of processes

such as inflammation, cell proliferation and contraction of the collagen lattice (Burford et al. 2007). However, the presence of oxygen free radicals or microbial infection hampers healing processes.

Despite remarkable development and advancements in the pharmaceutical industry, the search for more effective and low-cost therapeutic approaches for wound healing remains a challenge for modern medicine because of the need for long-term therapy and associated side-effects (Divakar et al. 2000; Soni and Singhai 2013). Naturally derived organic compounds/substances that are synthesised by primary or secondary metabolism in living organisms have been known for years (Estork et al. 2014; Rastogi et al. 2015), and are widely used in human therapy, veterinary medicine, agriculture and other areas (Martinez and Lujan 2011; Yakubu 2012; Moosavi et al. 2015).

Plants and their metabolites are the primary sources of novel bioactive compounds and are attractive alternative therapeutic options to synthetic drugs. The use of medicinal plants in health care is now a common practice (Hashemi and Davoodi 2011; Borges et al. 2016). Many studies have described the wound healing activity of medicinal plants (Purna and Sabu 2006; Kumar et al. 2007; Dawn et al. 2008).

Chromolaena odorata (L.) R.M. King and H. Robinson, is an ornamental plant usually considered to be one of the top 100 most invasive environmental weeds of wastelands, roadsides and other exposed areas in the world (GISD 2006; Chakraborty et al. 2011). This flowering shrub is native to North and Central America, and was later introduced to parts of Asia, Africa and Australia. *C. odorata* is also known by various other names such as Armstrong's weed, baby tea, bitter bush, butterfly weed, Christmas bush, devil weed, eupatorium, Jack in the bush, king weed, paraffin bush, paraffin weed, Siam weed, turpentine weed and triffid weed (Mc Fadyen 2004). It possesses insecticidal properties and is used as a green manure. It is also used for the preservation of dead bodies (Ukwueze et al. 2013).

The fresh leaves of *C. odorata* or the decoction has been used by practitioners of traditional medicine for the treatment of human burns, soft tissue wounds, ulcerated wounds, burn wounds, post-natal wounds and also for the treatment of leech bites, indigestion and skin infection (Panyaphu et al. 2011). The decoctions of the stems were reported to be effective against skin disease caused by

Propionibacterium acnes (Pandurangan et al. 2015). It is also used for the treatment of various ailments, such as amenorrhea, catarrh, cold-associated nasal congestion, diabetes, diarrhoea, fever, pertussis and rheumatism, and as a vermifuge (Goodall and Erasmus 1996). Other pharmacological properties of this plant include anthelmintic (Patel et al. 2010), antimalarial (Ongkana 2003), analgesic (Chakraborty et al. 2011), anti-inflammatory, antipyretic, antispasmodic (Oludare et al. 2000), antimycobacterial, insecticidal, antioxidant (Phan et al. 2001a), anti-gonorrhoeal (Caceres et al. 1995), fungicidal, diuretic (Gopinath et al. 2009), blood coagulating (Triaratana et al. 1991), and antimicrobial effects (Borges et al. 2016). However, at present there is only limited information available pertaining to the wound healing properties of the plant (Biswal et al. 1997). Hence, this study was designed to determine the phytochemical composition as well as the *in vivo* wound healing properties of ethanolic and aqueous extracts of *C. odorata* using an excision wound model.

The investigation of potent wound healing agents is one of the most promising areas in the field of biomedical sciences (Majumder 2012; Kameshwaran et al. 2014). Phytochemical screenings are important and are considered as the first step towards the discovery of potentially useful drugs (Sivamani et al. 2012). To understand such plants in detail and for them to assume their proper role in contributing to affordable healthcare, a robust scientific assessment is needed. Successive solvent extraction techniques, as well as chromatographic separations and spectroscopic methods have been used to determine the chemical constituents of plants and to study their bioactivity. Previous results have demonstrated that several secondary metabolites such as phenolic acids (protocatechuic, p-hydroxybenzoic, p-coumaric, ferulic and vanillic acids) isolated from various plants including *C. odorata* facilitate wound healing in various animal models (Phan et al. 2001a; Phan et al. 2001b; Paiva et al. 2002). Thus, we hypothesised that various phytochemicals present in *C. odorata* leaf extracts could have promising synergistic wound healing properties.

MATERIAL AND METHODS

Plant material collection and extraction. The leaves of *C. odorata* (Figure 1) were collected from

doi: 10.17221/161/2016-VETMED

the hilly regions of Ootacamund (Ooty), India and authenticated by Dr. B. Saraswathi (Director and Head, Siddha Medicines Division, Government Siddha Medical College, Chennai, India with voucher number LR/0078/MP/2014). Fresh leaves were washed thoroughly with distilled water and dried in the shade in a clean environment. The dry leaves were powdered and soaked in distilled water (1 : 5 w/v) at 37 °C. After 24 h, the supernatant was removed and the residue was soaked again in fresh distilled water for another 24 h. The whole process was repeated to ensure a complete extraction. The supernatants were pooled, filtered and centrifuged at 5000 g and 4 °C for 30 min. After centrifugation, the obtained supernatants were frozen at –20 °C and then lyophilised. For the preparation of the ethanol extract, the dried plant material was mixed

with ethanol in a ratio of 1 : 20. The extract was then filtered through Whatmann filter paper, and the filtrate was evaporated using a rotary flash evaporator to obtain a concentrated extract. The crude extract was then stored at –20 °C. Phytochemical analysis was carried out to identify the secondary metabolites present in the extracts using standard methods (Harborne 1984).

Determination of total phenol and lipid per-oxidation inhibition assay. Total phenolic content in the leaf extracts was determined using standard methods (Gulcin et al. 2003). One millilitre aliquots of extract or a standard solution of gallic acid were added to a volumetric flask containing 9 ml of water. Then, 1 ml of the Folin-Ciocalteu reagent was added to the mixture followed by vortexing. After 5 min, 10 ml of 7% sodium carbonate was added to

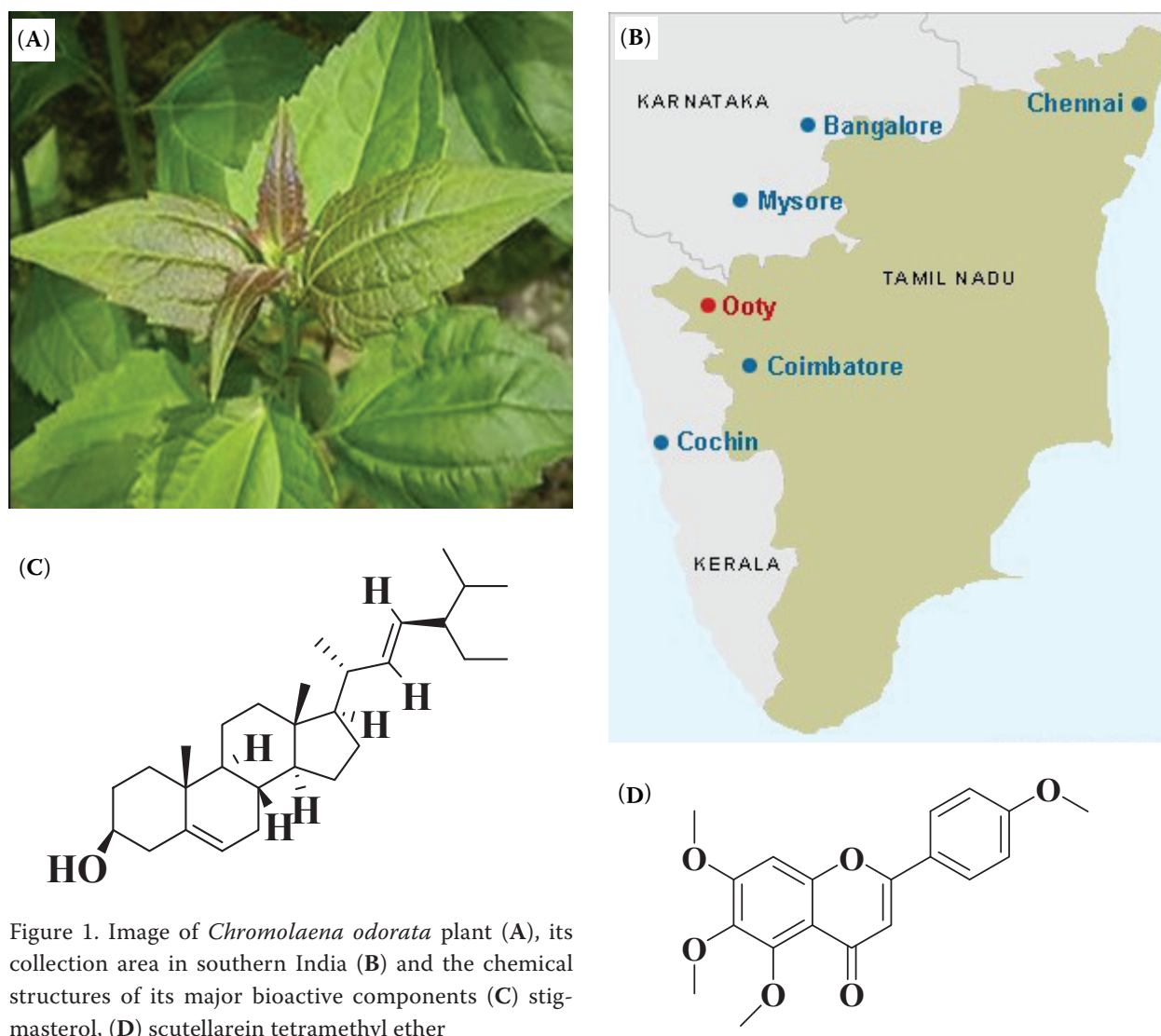


Figure 1. Image of *Chromolaena odorata* plant (A), its collection area in southern India (B) and the chemical structures of its major bioactive components (C) stigmasterol, (D) scutellarein tetramethyl ether

the mixture, which was then incubated for 90 min at 37 °C. The blank was prepared using distilled water and the absorbance against the blank was determined at 750 nm after the incubation period. The amount of phenolic content in the extract was estimated from the standard curve produced with different concentrations (10, 20, 30, 40, 50 µg/ml) of gallic acid. The total phenolic content of the plant was calculated using the following formula:

$$C = c \times m/V$$

where: C = total content of phenolic compound in gallic acid equivalent/g, c = the concentration of gallic acid established from the calibration curve (µg/ml), m = weight of the crude plant extract (g), V = volume of extract (ml)

The samples were analysed in triplicate. The lipid peroxidation inhibition ability of the extracts was evaluated using a modified procedure described by Lizcano et al. (2012). The percentage inhibition was calculated as follows:

$$I = [(ODc - ODs)/ODc] \times 100$$

where: I = lipid peroxidation inhibition (%), ODc = optical density control, ODs = optical density sample

The analysis was performed in triplicate.

Animals. World Health Organisation (WHO 2014, <http://www.who.int/mediacentre/factsheets/fs365/en/>), Geneva, and the Indian National Science Academy, New Delhi, guidelines for animal handling and care were followed in this study. This study was conducted based on the guidelines and approval of the Institutional Animal Ethical Committee (IAEC No. Biotech REC. 005/10). Eight-to-ten-week-old female Wistar albino rats (*Rattus norvegicus*) weighing 120–180 g were selected from an inbred colony and maintained under controlled conditions of temperature (23 ± 2 °C) and light (10 and 14 hours of light and dark, respectively). The animals had free access to sterile food and water. Three animals were housed in a polypropylene cage containing sterile paddy husk (procured locally) as bedding throughout the experiment. The animals were examined by a qualified veterinary surgeon and declared free of any parasites or worms before the experiment began. The cages were changed every two days to maintain aseptic conditions. The food and water consumption was monitored daily

throughout the duration of the experiment. Our animal weight observation chart (data not shown) showed that there was no change in the weight of the animals in any of the groups.

Excision wounds. The animals were anaesthetised using diethyl ether and then excision wounds were created on the rats as described by Morton and Malone (1972). The fur on the dorsal side (below the rib cage) of each animal was removed using a sterile shaving blade and the surface was decontaminated by wiping with sterile disinfectant. Then, on the shaved dorsal surface, a wound was inflicted by excising the skin flap in an aseptic fashion using sterile surgical knife, scissors and forceps. Each wounded rat was housed in a separate sterile polypropylene cage. The leaf extract was applied on alternate days on the wound surface and the wound was covered using sterile gauze. The wound size was calculated and granulation tissue was removed on the appropriate termination day (days 4, 8 and 16). Simple ointment base white petroleum jelly was used as vehicle control and the same was used to impregnate leaf extracts for the test group. Ten grams of petroleum jelly were weighed into a beaker and then melted in a water bath. The required quantities of the extract were weighed, added to the molten ointment base and triturated. The rats were divided into six groups of six to eight rats each. Group I rats were treated with simple ointment base (control), group II rats treated with a reference standard Betadine ointment, and groups III, IV, V and VI were treated with different (2.5, 5.0, 7.5, and 10%, respectively; w/w) concentrations of the extract (ethanolic or water extract) for 20 days. The ointment base and Betadine were applied in the same quantity to serve as control and standard, respectively. The wound contraction was calculated as the percentage reduction in wound area. On the fourth, eighth, twelfth and sixteenth days after the infliction of the initial wound, progressive change was observed in the wound areas. The wound surface areas were outlined using transparent paper and a graph sheet was used to measure the area of the wound. No animal death was observed in the control group, or in the reference standard drug or extract-treated group. The biochemical indicators hydroxyproline, hexosamine (Futamura et al. 2013; Gangwar et al. 2015) and total protein content were estimated from the excised tissue (Inkinen et al. 2000; Upadhyay et al. 2009).

doi: 10.17221/161/2016-VETMED

Table 1. Phytochemical analysis of aqueous and ethanolic leaf extracts of *Chromolaena odorata*

Phytochemicals	Ethanol	Aqueous
Tannins	+	+
Saponins	+	++
Flavonoids	+	+
Anthocyanins	–	–
Betacyanins	+	–
Quinones	+	–
Glycosides	+	–
Cardiac glycosides	++	–
Terpenoids	++	–
Phenols	++	++
Coumarins	–	+
Steroids	+	–
Alkaloids	–	++

++ = abundant, + = trace, – = absent

Histopathological examination. The experiment was terminated after appropriate treatment periods, i.e., after 0, 4, 8, 12 or 16 days of extract treatment and tissue was excised from the wound for histological examination. The sections were stained with haematoxylin and eosin (H&E) stains and the tissue samples were evaluated for the re-epithelisation of tissues, the width of the granular cell layer and the extent of tissue formation.

Statistical analysis. All experiments were performed in triplicate ($n = 3$), and the results were compared using a one-way analysis of variance (ANOVA). P -values of less than 0.05 ($P < 0.05$) were considered to indicate statistical significance.

RESULTS

Phytochemical screening conducted on leaf extracts of *C. odorata* revealed the presence of the following classes of primary and secondary me-

Table 2. Antioxidant activity (%) of *Chromolaena odorata* extracts

Concentration of extracts (µg/ml)	Aqueous extract	Ethanol extract	Gallic acid
100	75.00 ± 0.08	75.21 ± 0.01	80.06 ± 0.03
200	76.32 ± 0.09	77.06 ± 0.01	81.12 ± 0.02
300	77.12 ± 0.08	78.02 ± 0.02	81.72 ± 0.02

Table 3. Total phenol content of *Chromolaena odorata* leaf fractions

Extract (fractions)	Total phenol content equivalent to gallic acid (mg/g GAE)
Aqueous	0.22 ± 0.01
Ethanol	0.85 ± 0.06

tabolites: alkaloids, flavonoids, tannins, saponins, anthraquinones, cardiac glycosides and terpenoids in both ethanolic and water extracts, but with significant differences in relative concentrations, i.e., low, average or high (Table 1). Phytochemical screening of the aqueous extracts in this study revealed that they were rich in saponins and alkaloids, which have numerous pharmacological effects, and have been extensively used as drugs in the medical field. The detection of high levels of alkaloids in the leaf extracts of *C. odorata* further supports the presence of alkaloids in this plant, whereas ethanol extracts were rich in terpenoids and cardiac glycosides. However, both aqueous and ethanolic extracts showed high total phenol contents and also demonstrated high antioxidant and lipid peroxide inhibitory activity at 100, 200 and 300 µg/ml. The antioxidant activity for the aqueous and ethanolic extracts relative to gallic acid is shown in Table 2, the total phenol content for the aqueous and ethanolic extracts is shown in Table 3 and lipid peroxide inhibitory activity for the aqueous and ethanolic extracts is shown in Table 4.

Our results demonstrated improved wound healing within 16 days in *C. odorata*-treated rats, whereas it took more than 16 days in the standard and 20 days in the control rats. Wounds treated with the *C. odorata* extract showed no evidence of wound haemorrhage, oedema, inflammation and exudate. In contrast, untreated wounds displayed characteristic oedema associated with typical inflammation. In the *C. odorata*-treated rats, the skin surrounding the wound appeared to be regular and soft, while in the Betadine-treated group the skin

Table 4. Lipid peroxidation inhibition activity (%) of *C. odorata* extracts. Values are presented as the means of triplicate measurements ± SD

Concentration of extracts (µg/ml)	Aqueous extract	Ethanol extract
100	10.48 ± 0.09	12.78 ± 0.08
200	22.29 ± 1.35	28.48 ± 1.33
300	41.25 ± 2.22	31.11 ± 2.10

Table 5. Effect of topical application of *C. odorata* lyophilised aqueous leaf extract on wound area contraction (mm²). Values are presented as mean \pm SE; $n = 6$; (values do not differ significantly at $P < 0.05$)

Post wounding day	Excised wound control	<i>C. odorata</i> aqueous leaf extract concentration				Betadine concentration 5.0% (w/w)
		2.5% (w/w)	5.0% (w/w)	7.5% (w/w)	10.0% (w/w)	
Day 0	175.83 \pm 0.87	177.67 \pm 1.26	178.33 \pm 0.99	179.17 \pm 0.60	177.33 \pm 0.99	176.5 \pm 1.80
Day 8	140.50 \pm 4.60	124.50 \pm 2.79	114.18 \pm 3.48	121.33 \pm 3.57	133.00 \pm 3.17	128.83 \pm 5.28
Day 16	89.33 \pm 2.63	71.67 \pm 3.68	51.35 \pm 3.8	63.33 \pm 3.79	79.00 \pm 3.48	72.00 \pm 4.33

Wound area contraction (mm²) in response to different concentrations of *C. odorata* extract was calculated relative to excised wound control and standard reference control (Std-RC, Betadine) on days 0, 8 and 16

appeared totally dehydrated. Among various concentrations, 5.0% (w/w) was the most effective concentration of the *C. odorata* leaf extract for wound healing. The effect of topical application of different concentrations of the *C. odorata* leaf extract on the time required for wound healing is shown in Table 5. The animals treated with 5.0% *C. odorata* extract showed a significantly faster reduction in wound area than the untreated group on day 8 (114.18 versus 140.5 mm²) and day 16 (51.35 versus 89.33 mm²). Levels of hydroxyproline, hexosamine and total protein were also significantly increased in the rats treated with the 5.0% *C. odorata* extract (Table 6).

Haematoxylin and eosin (H&E) staining was performed to study the anatomical restoration elicited by treatment with the extract of *C. odorata*. Our results indicate that there was an increased formation of blood vessels and an improvement in cell proliferation after treatment with *C. odorata* leaf extract. When treated with different concentrations of the extract, the group of animals with excision wounds (Figure 2) showed significant differences compared to the normal and standard reference control (Figure 3).

DISCUSSION

Wound management entails a hospital stay of specific duration, expensive medication and vari-

ous surgical modalities followed by a long process of rehabilitation (Thomas et al. 2009). Most topical antibacterial agents and disinfectants are effective in protecting against infections, but the occurrence of irritations in the skin and allergy due to these agents reduces the rate of skin regeneration and increases the time needed for complete recovery (Burks 1998). Moreover, most expensive tissue-engineered wound dressings are out of reach for the patients residing in developing and underdeveloped countries. Many medicinal plants and products derived from medicinal plants have been shown to possess satisfactory wound healing efficacy with no or little toxicity and are less expensive than synthetic drugs. Some of the medicinal plants that have been investigated for their wound healing activity have already been used in traditional medicine for wound care (Phan et al. 2001b; Upadhyay et al. 2009; Hashemi and Davoodi 2011; Vaisakh and Pandey 2012).

Our phytoscreening results are in line with previous studies (Ling et al. 2005; Pandith et al. 2013) that were conducted using ethanolic seed extracts of *C. odorata*. However, the present investigation revealed that *C. odorata* aqueous extracts of varying concentrations can also exert significant cutaneous wound healing activity. The effects of the extract, Betadine ointment (standard), and normal base (control) in the excision wound model was evaluated by measuring the wound area and wound

Table 6. Effect of topical application of *C. odorata* aqueous leaf extract for seven days on various biochemical parameters in granulation tissue. Values are presented as mean \pm SE; $n = 6$

Group (mg/g tissue wt)	Excised wound control	<i>C. odorata</i> aqueous leaf extract concentration				Betadine concentration 5.0% (w/w)
		2.5% w/w	5.0% w/w	7.5% w/w	10.0% w/w	
Hydroxyproline	21.80 \pm 0.32	28.12 \pm 0.70*	30.99 \pm 0.82*	26.72 \pm 0.73*	23.19 \pm 0.80	25.73 \pm 0.67*
Hexosamine	0.50 \pm 0.04	0.55 \pm 0.03	0.69 \pm 0.04*	0.61 \pm 0.03*	0.60 \pm 0.03	0.53 \pm 0.03
Hexuronic acid	88.74 \pm 4.18	114.33 \pm 7.40*	123.77 \pm 7.77*	109.11 \pm 3.17*	97.51 \pm 3.61	109.78 \pm 4.16*

* $P < 0.05$ compared with excised wound control

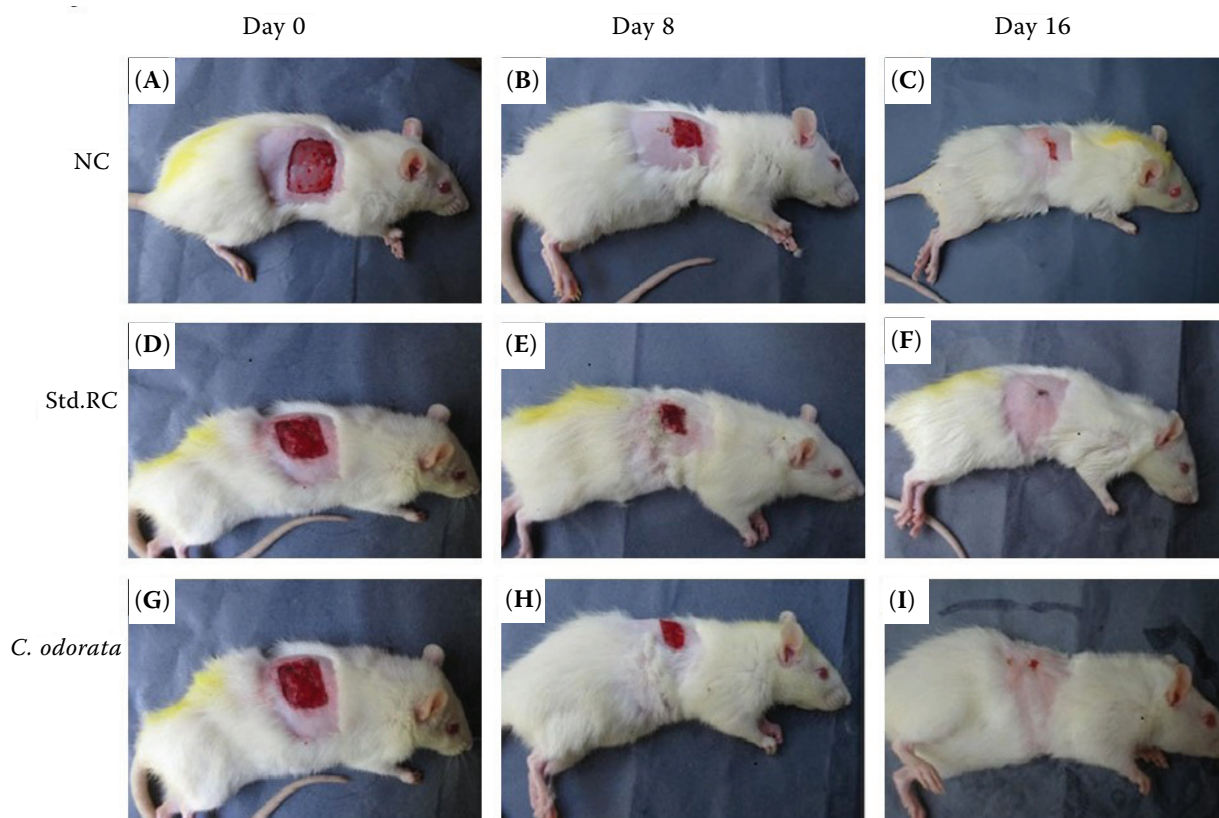


Figure 2. Various wound healing phases in negative control (NC) (A, B, C), standard reference control (Std.RC) and in response to 5% Betadine (D, E, F) and 5% *C. odorata* leaf extract (G, H, I)

contraction. The results indicate that healing is dependent on both the concentration as well as the nature of the different extracts (water vs ethanol). Our observations indicate that extracts with concentrations of more than 10% w/w could be lethal for animals. The potency of the extracts was found to be inversely proportional to the time needed for the healing of the wound. The activity of *C. odorata* was comparable with that of the reference drug Betadine, confirming the effectiveness of this medicinal plant in wound healing.

Wound repair consists of a cascade of events that re-establish the integrity of damaged tissues. The sequence of events that repairs the damage is categorised into four overlapping phases: haemostasis, inflammation, proliferation and tissue remodelling. Healing requires the collaborative efforts of numerous different tissues and cell lineages (Ling et al. 2005; Odunbaku et al. 2008). It involves platelet aggregation and blood clotting, fibrin formation, inflammatory responses to the injury, alteration in the inflammatory mediators, angiogenesis and re-epithelialisation. The healing process is not

complete until the disrupted surfaces are firmly closed together by collagen (Owoyele et al. 2008). The basic principle of optimal wound healing is to minimise tissue damage and to provide adequate tissue perfusion and oxygenation, proper nutrition, and a moist wound healing environment to restore the anatomical continuity and function of the affected region (Bamba et al. 1993).

The most established and discussed activity of *C. odorata* is its wound healing effect. The constituents of the plant's extracts modulate one or more of the overlapping wound healing stages. Leaf extracts and other plant parts of *C. odorata* (Table 6) have been shown to be beneficial in the treatment of wounds and other disorders (Bani 2002; Gosain and DiPietro 2004; Raina et al. 2008; Ayyanar and Ignacimuthu 2009; Nguyen et al. 2009). Traditionally, its leaves were ground into a paste and applied topically to the affected areas (Pandith et al. 2013). Both *in vitro* wound assay and *in vivo* studies have demonstrated that these extracts enhance the proliferation of fibroblasts, endothelial cells and keratinocytes; stimulate ke-

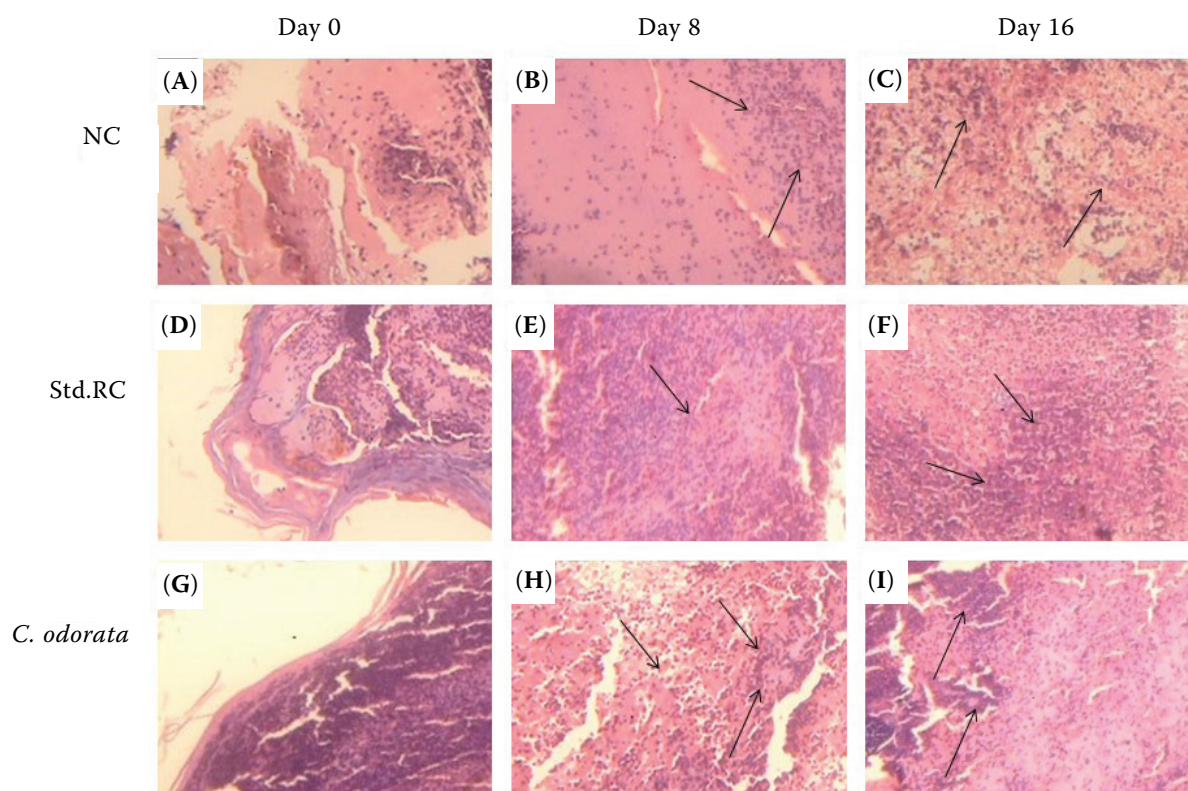


Figure 3. Histopathological evaluation demonstrates the healing effects observed (during the study period; day 0, day 8 and day 12) in the negative control (NC) (A, D, G), standard reference control (Std.RC) and in response to 5% Betadine (B, E, H) and 5% *C. odorata* leaf extract (C, F, I). Arrows indicate the wound healing granulation process

ratinoocyte migration; upregulate the keratinocyte-induced production of extracellular matrix proteins and basement membrane components including collagen VII, anchoring fibrils and fibrillin microfibrils; and inhibit collagen lattice contraction by fibroblasts (Kusano et al. 2001; Subramoniam et al. 2012).

Despite the natural cascades of the healing process, the process may be delayed by an infection caused by various mechanisms, such as decreased blood supply, which can promote impaired leukocyte function, prolong inflammatory and debridement phases, and produce proteolytic enzymes. Therefore, infection is the major impediment to the wound healing process and antibacterial compounds play a major role in the process of healing (Annan and Houghton 2008; Kahkeshani et al. 2013; Kumari et al. 2013). Medicinal plants, with their antioxidant, anti-inflammatory, and antimicrobial activities, harbour great potential for the management and treatment of wounds (Trabucchi et al. 1986; Trombetta et al. 2005; Akinmoladun et al. 2010). In the present study, leaf extracts of *C. odorata* induced better wound healing than

Betadine, a finding which was confirmed by the histopathological evaluation which showed complete re-epithelialisation, well-formed granulation tissue and neovascularisation. Betadine cream is the most commonly used topical antimicrobial agent for the treatment of injuries and wounds. It is widely used because it rapidly kills all bacteria and fungi commonly responsible for wound and skin infections. The present study suggests that the use of *C. odorata* leaf extracts would be highly beneficial for the treatment of wounds.

Another major challenge of pharmacological validation is that the exact mechanism of the wound healing process is often not clearly understood; hence, most research studies are restricted to screening plants to simply evaluate their wound healing effects and do not go into the mechanistic details. It is important to note that wound healing involves a number of processes, including inflammation, epithelialisation, antioxidant defence, biochemical change, granulation, neovascularisation and wound contraction. The possible mechanisms by which *C. odorata* can influence the different wound healing phases are briefly shown in Figure 4.

doi: 10.17221/161/2016-VETMED

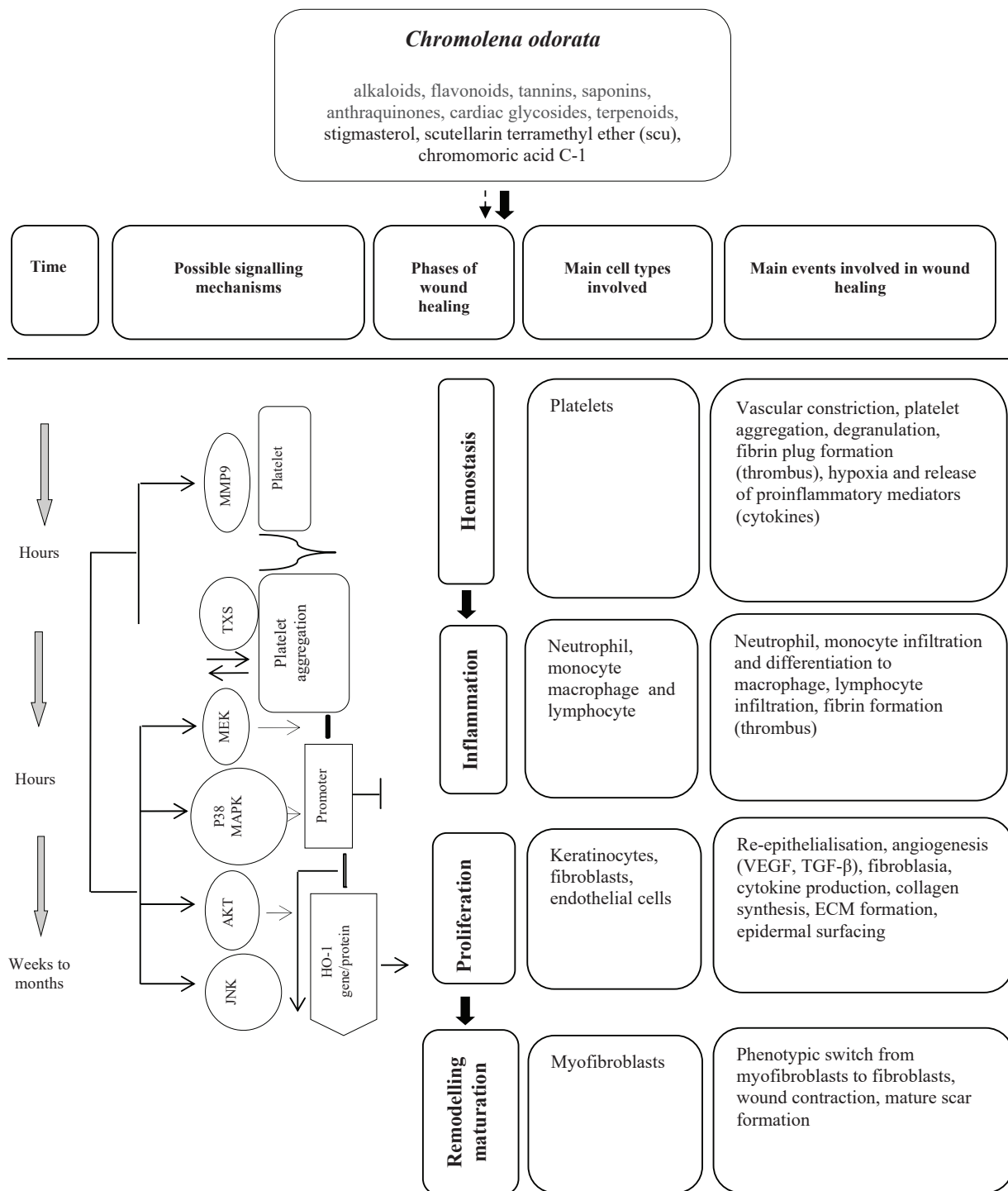


Figure 4. Schematic diagram showing the cellular and physiological events associated with *C. odorata* wound healing mechanisms and other pharmacological activities. *C. odorata* extract or its bioactive compounds stimulate haemostatic activity by stimulation of TXS and repression of MMP-9 expression. It also activates MEK, p38MAPK, AKT and JNK kinase pathways which initiate the expression of HO-1. The induction of HO-1 inhibits inflammation and stimulates cell proliferation, thereby enhancing the neovascularisation and cell migration that helps to accomplish wound healing. The dotted arrow represents bioactive compounds isolated from *C. odorata* that may be involved in the wound healing process individually or in combination, whereas the bold arrow indicates the definite involvement of scutellarein tetramethyl ether, stigmasterol and C1 in the process

Inflammation is a response to any tissue injury in the body caused by infection, trauma, chemicals, heat or unrecognised particles (Kim et al. 2006). Inflammation, which constitutes a part of the acute response, results in a coordinated influx of neutrophils to the wound site which, through their characteristic “respiratory burst” activity, produce free radicals (Pan et al. 2008). Topical application of compounds with free radical-scavenging properties in patients have shown to considerably improve wound healing and protect tissues from oxidative damage (Pisutthanan et al. 2005).

Proinflammatory cytokines like cyclooxygenase-2 and inducible nitric oxide synthase play a critical role in inflammation (Hanh et al. 2011). In addition, proinflammatory mediators such as prostaglandin E2 and nitric oxide enhance the expression of proinflammatory cytokines, including tumour necrosis factor- α and interleukin-1 β . Previous studies have demonstrated that *C. odorata* has anti-inflammatory activity both *in vitro* and *in vivo* (Lee et al. 2006; Karodi et al. 2009; Park et al. 2012). Scutellarein tetramethyl ether (4',5,6,7-tetramethoxy-flavone), isosakuranetin, and stigmasterol have also been reported to possess the anti-inflammatory activity (Trabucchi et al. 1986; Csupor et al. 2010).

The results of this study suggest that *C. odorata* would be a useful pharmaceutical ingredient for the management of excision wounds. This plant is also expected to heal other types of wounds including chronic ones; however, further studies have to be conducted in various wound models, and research at the cellular and molecular levels are required to identify the specific mechanism(s) that might induce healing in such wounds. Our results suggest that the inclusion of antipathogenic microbial extracts rich in antioxidants or fractions of *C. odorata* as a potential healing agent would also benefit human health. The data obtained in this study will be useful for future research aimed at further identifying the specific bioactive compounds other than scutellarein tetramethyl ether and stigmasterol (Pandith et al. 2013; Vijayaraghavan et al. 2017) that are responsible for the healing efficacy of *C. odorata*. Our results are in line with earlier reports (Grinell 1992) and we are in strong agreement with previously proposed signalling mechanisms of *C. odorata* in wound healing.

Besides the above, the secondary metabolites of living organisms including *C. odorata*-derived compounds are chemically and taxonomically ex-

tremely diverse. Thus, apart from participating in wound healing activity, they also play significant roles in treating various diseases (Sivamani et al. 2012; Yang et al. 2014; Borges et al. 2016) and are involved in other regulatory functions; these include hormonal functions, spermatogenesis (Yakubu 2012), growth and health promoters (Hashemi and Davoodi 2011), modulation of neutrophilic activity (Moosavi et al. 2015), blood clotting (Akomas and Ijioma 2014) and promotion of angiogenesis both in animals and humans (Morgan and Nigam 2013).

In summary, the present results indicate that *C. odorata* leaf extract stimulates wound healing. This is evident from the substantial increase in the rate of wound contraction and increased levels of hydroxyproline and hexosamine, which are necessary for wound healing. In addition, the enhanced proliferation of fibroblasts in the wound area implies that regeneration can be attributed to increased wound contraction. Hence, based on the present study we conclude that *C. odorata* is a promising wound healing agent. Our data also strongly suggest that the bioactive compounds found in the leaf extract may, after further study, play a significant role in treating various ailments in veterinary medicine and alternative medicine in humans in the future.

Acknowledgement

Authors thank Brulac Lab, Saveetha Dental College, Chennai for permitting us to conduct the animal experiments for this study.

REFERENCES

- Akinmoladun AC, Obuotor EM, Farombi EO (2010): Evaluation of antioxidant and free radical scavenging capacities of some Nigerian indigenous medicinal plants. *Journal of Medicinal Food* 13, 444–451.
- Akomas SC, Ijioma SN (2014): Bleeding and clotting time effect of ethanolic extracts of *Chromolaena odorata* versus *Ocimum gratissimum* treated albino rats. *Comprehensive Journal of Medical Sciences* 2, 9–13.
- Annan K, Houghton PJ (2008): Antibacterial, antioxidant and fibroblast growth stimulation of aqueous extracts of *Ficus asperifolia* Miq. and *Gossypium arboreum* L., wound-healing plants of Ghana. *Journal of Ethnopharmacology* 119, 141–144.

doi: 10.17221/161/2016-VETMED

- Ayyanar M, Ignacimuthu S (2009): Herbal medicines for wound healing among tribal people in Southern India: Ethnobotanical and Scientific evidences. *International Journal of Applied Research in Natural Products* 2, 29–42.
- Bamba D, Bessiere JM, Marion C, Pelissier Y, Fouraste I (1993): Essential oil of *Eupatorium odoratum*. *Planta Medica* 59, 184–185.
- Bani G (2002): Status and management of *Chromolaena odorata* in Congo. In: Zachariades C, Muniappan R, Strathie L (eds): *Proceedings of the Fifth International Workshop on Biological Control and Management of Chromolaena odorata*. Durban, South Africa, October 2000. 71–73.
- Belmont PJ, Schoenfeld AJ, Goodman G (2010): Epidemiology of combat wounds in operation iraqi freedom and operation enduring freedom: Orthopaedic burden of disease. *Journal of Surgical Orthopedic Advances* 19, 2–7.
- Biswal PR, Sardar KK, Parija SC, Mishra PR, Mishra SN (1997): Wound healing effect of *Eupatorium odoratum* Linn. and Himax in rabbits. *Indian Journal of Indigenous Medicine* 19, 71–74.
- Borges A, Abreu AC, Dias C, Saavedra MJ, Borges F, Simoes M (2016): New perspectives on the use of phytochemicals as an emergent strategy to control bacterial infections including biofilms. *Molecules* 21, doi: 10.3390/molecules21070877.
- Burford G, Bodeker G, Ryan TJ (2007): Skin and wound care: traditional, complementary and alternative medicine in public health dermatology. In: Bodeker G, Burford G (eds): *Traditional, Complementary and Alternative Medicine: Policy and Public Health Perspectives*. 1st edn. Imperial College Press, London. 472 pp.
- Burks RI (1998): Povidone-iodine solution in wound treatment. *Physical Therapy* 78, 212–218.
- Caceres A, Menendez H, Mendez E, Cohobon E, Samayoa BE, Jauregui E, Peralta E, Carrillo G (1995): Antigonorrhoeal activity of plants used in Guatemala for the treatment of sexually transmitted diseases. *Journal of Ethnopharmacology* 48, 85–88.
- Chakraborty AK, Sujit R, Umesh KP (2011): *Chromolaena odorata* (L.): An overview. *Journal of Pharmacy Research* 43, 573–576.
- Csupor D, Blazso G, Balogh A, Hohmann J (2010): The traditional Hungarian medicinal plant *Centaurea sadleriana* Janka accelerates wound healing in rats. *Journal of Ethnopharmacology* 127, 193–195.
- Dawn TA, Jialin W, Zhihong J, Hubiao C, Guanghua L, Zhongzhen Z (2008): Ethnobotanical study of medicinal plants used by Hakka in Guangdong, China. *Journal of Ethnopharmacology* 117, 41–50.
- Divakar MC, Devi LS, Kumar S, Rao SB (2000): Studies on wound healing property of *Polyscias scutellaria* leaf saponins. *Indian Journal of Natural Products* 17, 37–42.
- Edlich RF, Winters KL, Britt LD, Long WB, Gubler KD, Drake DB (2005): Difficult wounds: an update. *Journal of Long Term Effective Medical Implants* 15, 289–302.
- Estork DM, Gusmao DF, Paciencia ML, Diaz IE, Varella AD, Younes RN, Reis LF, Montero EF, Bernardi MM, Suffredini IB (2014): First chemical evaluation and toxicity of *Cas- inga-cheirosa* to Balb-c male mice. *Molecules* 19, 3973–3987.
- Futamura A, Higashiguchi T, Ito A, Kodama Y, Chihara T, Kaneko T, Tomatsu A, Shimpo K (2013): Experimental research on stimulation of wound healing by n-3 fatty acids. *Wounds – A Compendium of Clinical Research and Practice* 25, 186–192.
- Gangwar M, Gautam MK, Ghildiyal S, Nath G, Goel RK (2015): *Mallotus philippinensis* Muell. Arg fruit glandular hairs extract promotes wound healing on different wound model in rats. *BMC Complementary Alternative Medicine* 15, doi: 10.1186/s12906-015-0647-y.
- GISD – Global Invasive Species Database (2006): Global Invasive Species Database online data sheet. *Chromolaena odorata* (herb). Available at <http://www.iucngisd.org/gisd/species.php?sc=47>. (Accessed November 1, 2016).
- Goodall JM, Erasmus DJ (1996): Review of the status and integrated control of the invasive alien weed, *Chromolaena odorata*, in South Africa. *Agriculture, Ecosystems and Environment* 56, 151–164.
- Gopinath R, Sunilson JAJ, Radhamani S, Das A, Nilugal K (2009): Diuretic activity of *Eupatorium odoratum* (L.). *Journal of Pharmaceutical Research* 2, 844–846.
- Gosain A, DiPietro LA (2004): Aging and wound healing. *World Journal of Surgery* 28, 321–326.
- Grinell F (1992): Cell adhesion. In: Cohen IK, Diegelmann RF, Lindblad WJ (eds): *Wound Healing: Biochemistry of Clinical Aspects*. Saunders WB, Philadelphia. 209–222.
- Gulcin L, Sat GI, Beydemir S, Elmastas M, Kufrevioglu OI (2003): Comparison of antioxidant activity of clove (*Eugenia caryophyllata* Thumb.) buds and lavender (*Lavandula stoechas* L.). *Food Chemistry* 87, 393–400.
- Hanh TT, Hang DT, Van Minh C, Dat N (2011): Anti-inflammatory effects of fatty acids isolated from *Chromolaena odorata*. *Asian Pacific Journal of Tropical Medicine* 4, 760–763.
- Harborne JB (1984): *Phytochemical methods – a guide to modern techniques of plant analysis*. 2nd edn. Springer Netherlands. 4–16.
- Hashemi SR, Davoodi H (2011): Herbal plants and their derivatives as growth and health promoters in animal

- nutrition. *Veterinary Research Communications* 35, 169–180.
- Hostetler SG, Xiang H, Gupta S, Sen C, Gordillo JM (2006): Discharge patterns of injury-related hospitalizations with an acute wound in the United States. *Wounds* 1, 340–351.
- Inkinen K, Turakainen H, Wolff H, Ravanti L, Kahari VM, Ahonen J (2000): Expression and activity of matrix metalloproteinase-2 and -9 in 649 experimental granulation tissue. *Apmis* 108, 318–328.
- Kahkeshani N, Farahanikia B, Mahdavian P, Abdolghaffari A, Hassanzadeh G, Abdollahi M (2013): Antioxidant and burn healing potential of *Galium odoratum* extracts. *Research in Pharmaceutical Sciences* 8, 197–203.
- Kameshwaran S, Senthilkumar R, Thenmozhi S, Dhanalakshmi M (2014): Wound healing potential of ethanolic extract of *Tecoma stans* flowers in rats. *Pharmacology* 5, 215–221.
- Karodi R, Jadhav M, Rub R, Bafna A (2009): Evaluation of the wound healing activity of a crude extract of *Rubia cordifolia* L. (Indian madder) in mice. *International Journal of Applied Research and Natural Products* 2, 12–18.
- Kim JH, Kim DH, Baek SH, Lee HJ, Kim MR, Kwon HJ, Lee CH (2006): Rengyolone inhibits inducible nitric oxide synthase expression and nitric oxide production by down-regulation of NF- κ B and p38 MAP kinase activity in LPS stimulated RAW 264.7 cells. *Biochemical Pharmacology* 71, 1198–1205.
- Kumar B, Vijayakumar M, Govindarajan R, Pushpangadan P (2007): Ethnopharmacological approaches to wound healing – Exploring medicinal plants of India. *Journal of Ethnopharmacology* 114, 103–113.
- Kumari P, Yadav P, Verma PR, Kumar S, Arya A (2013): A review on wound healing properties of Indian medicinal plants. *Indian Journal of Fundamental and Applied Life Sciences* 3, 220–232.
- Kusano A, Seyama Y, Nagai M, Shibano M, Kusano G (2001): Effects of fukinolic acid and cimicifugic acids from *Cimicifuga* species on collagenolytic activity. *Biological Pharmaceutical Bulletin* 24, 1198–1201.
- Lee IS, Jin W, Zhang X, Hung TM, Song KS, Seong YH, Bae K (2006): Cytotoxic and COX-2 inhibitory constituents from the aerial parts of *Aralia cordata*. *Archives of Pharmacological Research* 29, 548–555.
- Ling SK, Mazura MP, Khoo MGH, Virimala S, Ong BK, Mastura M, Nor Azah MA, Salbiah M, Siti Asha ABL and Rasadah MA (2005): Chemical constituents and therapeutic potential of the leaf extracts from *Chromolaena odorata*. In: Nik Zanariah NM, Norhara H, Nor Azman H, Chan HT (eds): *Highlights of FRIM's IRPA Projects 2005. Identifying Potential Commercial Collaborations Project Evaluation Meeting*. Forest Research Institute Malaysia, Malaysia. 108–114.
- Lizcano LJ, Viloria BM, Vicente R, Berrueta LA, Gallo B, Martinez-Canamero M, Ruiz-Larrea MB, Ruiz-Sanz JI (2012): Lipid oxidation inhibitory effects and phenolic composition of aqueous extracts from medicinal plants of Colombian Amazonia. *International Journal of Molecular Sciences* 13, 5454–5467.
- Majumder P (2012): Taxo-cognostic, Phyto-physicochemical & Biological screening of a plant: Taxo-cognostic, Phytochemical, Physicochemical parameters & Biological screening of *Zyziphus oenopia* (L.) Mill plant root. LAP Lambert Academic Publishing. 72 pp.
- Martinez GJ, Lujan MC (2011): Medicinal plants used for traditional veterinary in the Sierras de Cordoba (Argentina): An ethnobotanical comparison with human medicinal uses. *Journal of Ethnobiology and Ethnomedicine* 7, 23.
- McFadyen RE (2004): *Chromolaena* in East Timor: history, extent and control. In: Day MD, McFadyen RE (eds): *Chromolaena in the Asia-Pacific Region. Proceedings of the 6th International Workshop on Biological Control and Management of Chromolaena odorata*. ACIAR Technical Reports 55, Canberra, Australia: ACIAR. 8–10.
- Meenakshi S, Raghavan G, Nath V, Ajay Kumar SR, Shanta M (2006): Antimicrobial, wound healing and antioxidant activity of *Plagiochasma appendiculatum* Lehm. et. Lind. *Journal of Ethnopharmacology* 107, 67–72.
- Morgan C, Nigam Y (2013): Naturally derived factors and their role in the promotion of angiogenesis for the healing of chronic wounds. *Angiogenesis* 16, 493–502.
- Morton JJ, Malone MH (1972): Evaluation of vulnerary activity by an open wound procedure in rats. *Archives of International Pharmacodynamics and Therapeutics* 196, 117–126.
- Moosavi F, Hosseini R, Saso L, Firuzi O (2015): Modulation of neurotrophic signalling pathways by polyphenols. *Drug Design Development Therapy* 10, 23–42.
- Nagori BP, Solanki R (2011): Role of medicinal plants in wound healing. *Research Journal of Medicinal Plants* 5, 392–405.
- Nguyen DT, Orgill DP, Murphy GF (2009): The pathophysiologic basis for wound healing and cutaneous regeneration. In: Orgill D, Blanco G (eds): *Biomaterials for Treating Skin Loss*. Woodhead Publishing. 25–57.
- Odunbaku OA, Ilusanya OA, Akasoro KS (2008): Antibacterial activity of ethanolic leaf extract of *Ficus exasperata* on *Escherichia coli* and *Staphylococcus albus*. *Scientific Research and Essays* 3, 562–564.
- Oludare TB, Olumayokun OA, Olufunmilola SO, Modupe MJ (2000): Anti-inflammatory, antipyretic and antispasmodic properties of *Chromolaena odorata*. *Pharmaceutical Biology* 38, 367–370.

doi: 10.17221/161/2016-VETMED

- Ongkana R (2003): Phytochemistry and antimalarial activity of *Eupatorium odoratum* L. *International Journal of Pharmaceutical Research* 4, 573–576.
- Owoyele BV, Oguntoye SO, Dare K, Ogunbiyi BA, Aruboula EA, Soladoye AO (2008): Analgesic, anti-inflammatory and antipyretic activities from flavonoid fractions of *Chromolaena odorata*. *Journal of Medical Plant Research* 2, 219–225.
- Paiva LA, de Alencar Cunha KM, Santos FA, Gramosa NV, Silveira ER, Rao VS (2002): Investigation on the wound healing activity of oleo-resin from *Copaifera langsdorffii* in rats. *Phytotherapy Research* 16, 737–739.
- Pan CH, Kim ES, Jung SH, Nho CW, Lee JK (2008): Tectorigenin inhibits IFN- γ /LPS-induced inflammatory responses in murine macrophage RAW 264.7 cells. *Archives of Pharmacol Research* 31, 1447–1456.
- Pandith H, Zhang X, Thongpraditchote S, Wongkrajang Y, Gritsanapan W, Baek SJ (2013): Effect of Siam weed extract and its bioactive component scutellarein tetramethyl ether on anti-inflammatory activity through NF- κ B pathway. *Journal of Ethnopharmacology* 147, 434–441.
- Pandurangan A, Kavita R, Apoorva S (2015): Evaluation of antimicrobial and anthelmintic activity of leaves of *Chromolaena odorata*. *International Bulletin of Drug Research* 5, 64–71.
- Panyaphu K, On TV, Sirisa-Ard P, Srisa-Nga P, ChansaKaow S, Nathakarnkitkul S (2011): Medicinal plants of the Mien (Yao) in Northern Thailand and their potential value in the primary healthcare of postpartum women. *Journal of Ethnopharmacology* 135, 226–237.
- Park JW, Kwon OK, Jang H, Jeong H, Oh SR, Lee HK, Han SB, Ahn KS (2012): A leaf methanolic extract of *Wercklea insignis* attenuates the lipopolysaccharide-induced inflammatory response by blocking the NF- κ B signaling pathway in RAW 264.7 macrophages. *Inflammation* 35, 321–331.
- Patel J, Kumar GS, Qureshi MS, Jena PK (2010): Anthelmintic activity of ethanolic extract of whole plant of *Eupatorium odoratum*. *International Journal of Phytomedicine* 2, 127–132.
- Phan TT, Wang L, See P, Grayer RJ, Chan SY, Lee ST (2001a): Phenolic compounds of *Chromolaena odorata* protect cultured skin cells from oxidative damage: Implication for cutaneous wound healing. *Biological and Pharmaceutical Bulletin* 24, 1373–1379.
- Phan TT, Hughes MA, Cherry GW (2001b): Effects of an aqueous extract from the leaves of *Chromolaena odorata* (Eupolin) on the proliferation of human keratinocytes and on their migration in an in vitro model of reepithelialization. *Wound Repair Regeneration* 9, 305–313.
- Pisutthanan N, Liawruangrath S, Bremner J, Liawruangrath B (2005): Chemical constituents and biological activities of *Chromolaena odorata*. *Journal of Chiang Mai University* 32, 139–148.
- Purna SK, Babu M (2006): Collagen based dressings – a review. *Burns* 26, 54–62.
- Raina R, Parwez S, Verma PK, Pankaj NK (2008): Medicinal plants and their role in wound healing. *Online Veterinary Journal* 3, 21.
- Rastogi S, Pandey MK, Prakash J, Sharma A, Singh GN (2015): Veterinary herbal medicines in India. *Pharmacognosy Review* 9, 155–163.
- Sivamani RK, Ma BR, Wehrli LN, Maverakis E (2012): Phytochemicals and naturally derived substances for wound healing. *Advances in Wound Care (New Rochelle)* 1, 213–217.
- Soni H, Singhai AK (2013): A recent update of botanicals for wound healing activity. *International Research Journal of Pharmacy* 3, 1–7.
- Subramoniam A, Asha VV, Nair SA, Sasidharan SP, Sureshkumar PK, Rajendran KN, Karunakaran D, Ramalingam K (2012): Chlorophyll revisited anti-inflammatory activities of chlorophyll a and inhibition of expression of TNF- α gene by the same. *Inflammation* 35, 959–966.
- Thomas GW, Rael LT, Bar-Or R, Shimonkevitz R, Mains CW, Slone DS, Craun ML, Bar-Or D (2009): Mechanisms of delayed wound healing by commonly used antiseptics. *Journal of Trauma* 66, 82–90.
- Trabucchi E, Preis-Baruffaldi F, Baratti C, Montorsi W (1986): Topical treatment of experimental skin lesions in rats: macroscopic, microscopic and scanning electron-microscopic evaluation of the healing process. *International Journal of Tissue Reaction* 8, 533–544.
- Triaratana T, Suwannuraks R, Naengchomnong W (1991): Effects of *Eupatorium odoratum* on blood coagulation. *Journal of the Medical Association of Thailand* 74, 283–287.
- Trombetta D, Castelli F, Sarpietro MG, Venuti V, Cristani M, Daniele C, Saija A, Mazzanti G, Bisignano G (2005): Mechanisms of antibacterial action of three monoterpenes. *Antimicrobial Agents and Chemotherapy* 49, 2474–2478.
- Ukwueze ES, Duru OM, Shorinwa OA (2013): Evaluation of the cutaneous wound healing activity of solvent fractions of *chromolaena odorata* linn. *Indo American Journal of Pharmaceutical Research* 3, 3316–3323.
- Upadhyay NK, Kumar R, Mandotra SK (2009): Safety and healing efficacy of Sea buckthorn (*Hippophae rhamnoides* L.) seed oil on burn wounds in rats. *Food and Chemical Toxicology* 47, 1146–1153.
- Vaisakh MN, Pandey A (2012): Assessment of flavonoid release with different permeation enhancers. *International Journal of Pharmaceutical Science and Drug Research* 4, 154–156.

doi: 10.17221/161/2016-VETMED

- Vijayaraghavan K, Rajkumar J, Bukhari SN, Al-Sayed B, Seyed MA (2017): *Chromolaena odorata*: A neglected weed with a wide spectrum of pharmacological activities (Review). *Molecular Medicine Reports* 15, 1007–1016.
- Wietecha MS, DiPietro LA (2013): Therapeutic approaches to the regulation of wound angiogenesis. *Advances in Wound Care (New Rochelle)* 2, 81–86.
- Yakubu MT (2012): Effect of a 60-day oral gavage of a crude alkaloid extract from *Chromolaena odorata* leaves on hormonal and spermatogenic indices of male rats. *Journal of Andrology* 33, 1199–1207.
- Yang X, Wen K, Tin C, Li G, Wang H, Kocher J, Pelzer K, Ryan E, Yuan L (2014): Dietary rice bran protects against rotavirus diarrhea and promotes Th1-type immune responses to human rotavirus vaccine in gnotobiotic pigs. *Clinical Vaccine Immunology* 21, 1396–1403.

Received: November 14, 2016

Accepted after corrections: September 9, 2017