

First report of ticks in the subcutaneous tissue of the raccoon dog *Nyctereutes procyonoides*

A. MATYSIAK^{1,2*}, O. WASIELEWSKI¹, J. WŁODAREK³, A. ONDREJKOVA²,
P. TRYJANOWSKI¹

¹Institute of Zoology, Poznan University of Life Sciences, Poland

²Department of Epizootiology and Parasitology, University of Veterinary Medicine and Pharmacy in Kosice, Slovakia

³Department of Preclinical Sciences and Infectious Diseases, Poznan University of Life Sciences, Poland

*Corresponding author: alicjamatysiak@gmail.com

ABSTRACT: Ticks are common ectoparasites of animals; they also carry many tick-borne pathogens that are often detrimental for the health of both animals and humans. These parasites have been found in subcutaneous tissue, mainly in red foxes (*Vulpes vulpes*), but the reason for this is unknown. In this study we report the first occurrence of the tick in an unusual location in the subcutaneous tissue of the raccoon dog *Nyctereutes procyonoides*. The study was carried out on two adult male raccoon dogs, hunted in Western Poland. After the necropsy, one was found to have a partially decomposed tick, a female *Ixodes ricinus*, in the groin region.

Keywords: ectoparasites; *Ixodes ricinus*; Poland; wild carnivores

The raccoon dog (*Nyctereutes procyonoides*) is native to eastern Siberia, China, North Vietnam, Korea and Japan (Nowak 1984; Pitra et al. 2010). However, between 1928 and 1955, approximately 9000 individuals were introduced into the European part of the former Soviet Union, for use in fur production (Lavrov 1971). Raccoon dogs have adapted very well to the environment of Eastern Europe, and they have gradually spread to the north and west. Raccoon dogs are now present in central and northern Europe, from Finland in the north, to Bulgaria and Serbia in the south, and from western Russia, Ukraine and Belarus in the east, to Germany to the west (Nowak 1984; Kauhala and Helle 1995). In Poland, the presence of this species was first recorded in the 1950s (Dehnel 1956), and since then it has gradually expanded its distribution (Nowak 1973). The raccoon dog is the only canine who spends the winter hibernating in areas with a harsh climate, which is enabled the prior accumulation of large amounts of fat (Kauhala 1993; Kauhala and Saeki 2004).

The raccoon dog is known to be a carrier of dangerous diseases and parasites such as rabies, canine distemper virus, *Sarcoptes scabiei*, *Echinococcus multilocularis* and *Trichinella* spp. (Badr et al. 2005; Al-Sabi et al. 2013; Mulder 2013; Duscher et al. 2017). Frequent contact of the invasive raccoon dog (*Nyctereutes procyonoides*) with the Eurasian badger (*Meles meles*) and the red fox (*Vulpes vulpes*) increases the risk of the spread of zoonoses (Kowalczyk et al. 2008).

In European raccoon dogs, ticks of the Ixodidae family (*Ixodes ricinus*, *I. canisuga*, *I. rugicollis* and *I. hexagonus*) are found most often (Siuda 1993; Paulauskas et al. 2012; Wodecka et al. 2016). In Asia (Japan and South Korea), the species *I. ovatus*, *I. persulcatus*, *I. pavlovskyi*, *I. tanuki*, *I. nipponensis*, *Haemaphysalis flava*, *H. leporispalustris*, *H. longicornis* and *Amblyomma testudinarium* have also been described (Nakao and Miyamoto 1993; Lee et al. 1997; Yamauchi et al. 2012; Kim et al. 2014).

As ectoparasites, ticks are commonly found on wild carnivores. There are also cases where these

parasites are found in subcutaneous tissue. Most of the known cases of ticks in subcutaneous tissue come from red foxes (Nuttall 1914; Drozd 1958; Lebeda 1962; Smith et al. 1986; Petko and Stanko 1991; D'Amico et al. 2017). To our knowledge, their presence in the subcutaneous tissue of raccoon dogs has not been recorded.

Thus, the present study is the first description of a subcutaneous tick in a raccoon dog.

Case description

Three raccoon dogs shot by hunters in 2017 in Western Poland were provided to the Institute of Zoology for research purposes (Poznan University of Life Sciences).

Firstly, the animals were subjected to external inspections at the location of shooting where they were checked for ectoparasites such as ticks or fleas. Then, within 24 hours they were transported to the Institute of Zoology and thoroughly examined for subcutaneous ticks. For this purpose, the animals were skinned, which involved scalping of the skull, through the limbs, to the tip of the tail, as numerous ticks are found at the base of the tail in foxes.

Case 1. An adult male raccoon dog, weighing 7.75 kg, was shot in September 2017 in the Kuslin commune (52°22'N 16°19'E). After external inspection, no ectoparasites, including ticks, were found. After removing the skin, a small dark nodule was found in the region of the left groin. This element was easily excised and stored in ethyl alcohol until further analysis. During the microscopic observation of the removed element, it turned out that the element was encapsulated. After opening it was noted to be part of a decomposed tick. The area was fragmented, but gnathosoma and scutum were well preserved. The tick appeared in a typical position with the palpi turned backwards. On this basis, the tick was identified as a female *Ixodes ricinus* (Figure 1).

Case 2. An adult male raccoon dog in adulthood, weighing 7.04 kg, was shot in October 2017 in the Granowo commune (52°13'N 16°32'E) and was subjected to external examination. Two ticks were found on the right ear and placed in ependorfs with ethyl alcohol until further analysis. After the section was performed, no black nodules were detected in the subcutaneous tissue. Based on microscopic observation, the externally collected



Figure 1. View of the gnathosoma (dorsal and ventral) and scutum of the examined female tick, *Ixodes ricinus*

ticks were identified as one male and one female of *Dermacentor reticulatus*.

Case 3. An adult male raccoon dog, weighing 5.10 kg, was shot in February 2018 in the Grodzisk Wielkopolski commune (52°14'N 16°22'E). The animal was in very poor physical condition and was emaciated with scabies. After removing the skin, a small dark nodule was found in the region of the left ear subcutaneously (Figure 2). It was identified as a female of *Ixodes ricinus*.

DISCUSSION AND CONCLUSIONS

We found *Ixodes ricinus* ticks in the subcutaneous tissue of a raccoon dog (Figure 1). This is the first described case of a tick in the subcutaneous tissue of these animals. Most reports on this topic relate to foxes. The occurrence of *Ixodes ricinus* ticks in subcutaneous tissue was noted in foxes in Eastern Europe (Nuttall 1914; Drozd 1958; Petko and Stanko 1991; D'Amico et al. 2017), *I. hexago-*

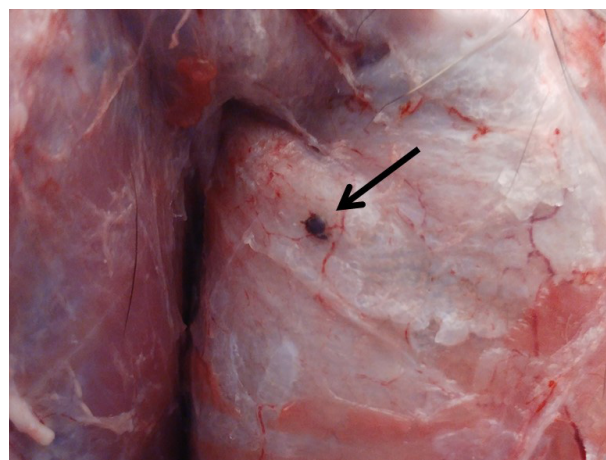


Figure 2. Visceral side of the skin of the raccoon dog at the left ear region showing female *Ixodes ricinus*

<https://doi.org/10.17221/38/2018-VETMED>

nus, *I. crenulatus*, and *Dermacentor reticulatus* (D'Amico et al. 2017). Interestingly, another tick species, *Amblyomma americanum*, was found in the subcutaneous tissue of a red fox in the United States (Smith et al. 1986). Besides wild animals, the described phenomenon was also observed in a dog in Sweden (Zakrisson 2010) and a child in South Korea (Chang et al. 2006).

So far, knowledge on this subject is very limited. The subcutaneous location of ticks may be related to their hosts, rather than to their own biology. According to Portman and Dalke (1945) and Tugwell and Lancaster (1962), the long hypostome of a tick causes a local reaction in the tissue that involves swelling, absorbing the entire tick. Also, Nuttall (1914) claimed that when the tick is inserted under the skin, an oedema develops which increases and includes the tick. In larger species of ticks from the genus *Amblyomma*, the oedema covers only a part of the tick, while in smaller *Ixodes*, the swelling covers the entire tick. The presence of ticks in the subcutaneous tissue is not caused by tick activity. This is because, at the site of anchorage with the hypostome, swelling of the skin develops, which grows and increases on the anchored tick and absorbs it completely. In the area where the tick is absorbed, the wound becomes overgrown and there is no scar. This seems to be related to the long hypostome which is characteristic for *Ixodes* and which facilitates penetration. However, after infiltrating the subcutaneous tissue, ticks that are surrounded by connective tissue are unable to survive and die after a time.

Ticks can be rarely found in the subcutaneous tissues of raccoon dogs. To our knowledge, this case of a tick in the subcutaneous tissue of a raccoon dog is the first such report in the scientific literature.

Acknowledgements

We express our thanks to Prof. Tim H. Sparks for language proofreading. We are grateful to the hunter groups “Drop 18” and “Ponowa 15” for providing raccoon dogs cadavers.

REFERENCES

- Al-Sabi MNS, Chriel M, Jensen TH, Enemark HL (2013): Endoparasites of the raccoon dog (*Nyctereutes procyonoides*) and the red fox (*Vulpes vulpes*) in Denmark 2009–2012 – A comparative study. *International Journal for Parasitology: Parasites and Wildlife* 2, 144–151.
- Badr V, Stefan P, Preisler J (2005): *Trichodectes canis* (De Geer, 1778) (Phthiraptera, Ischnocera), a new ectoparasite of the raccoon dog (*Nyctereutes procyonoides*) in the Czech Republic. *European Journal of Wildlife Research* 51, 133–135.
- Chang SH, Park JH, Kwak JE, Joo M, Kim H, Chi JG, Hong ST, Chai JY (2006): A case of histologically diagnosed tick infestation on the scalp of a Korean child. *The Korean Journal of Parasitology* 44, 157–161.
- D'Amico G, Jurankova J, Tabaran FA, Frgelecova L, Forejtek P, Matei IA, Ionica AM, Hodzic A, Modry D, Mihalca AD (2017): Occurrence of ticks in the subcutaneous tissue of red foxes, *Vulpes vulpes* in Czech Republic and Romania. *Ticks and Tick-Borne Diseases* 8, 309–312.
- Dehnel A (1956): New species of mammal in Polish fauna *Nyctereutes procynoides* (Gray) (in Polish). *Chronmy Przyrode Ojczysta* 12, 17–21.
- Drozd J (1958): Penetration of *Ixodes ricinus* under the skin of the host. *Acta Parasitologica Polonica* 6, 383–385.
- Duscher T, Hodzic A, Glawischnig W, Duscher GG (2017): The raccoon dog (*Nyctereutes procyonoides*) and the raccoon (*Procyon lotor*) – their role and impact of maintaining and transmitting zoonotic diseases in Austria, Central Europe. *Parasitology Research* 116, 1411–1416.
- Kauhala K (1993): Growth, size, and fat reserves of the raccoon dog in Finland. *Acta Theriologica* 38, 139–150.
- Kauhala K, Helle E (1995): Population ecology of the raccoon dog in Finland – a synthesis. *Wildlife Biology* 1, 3–9.
- Kauhala K, Saeki M (2004): Finnish and Japanese raccoon dogs – on the road to speciation? In: Macdonald DW, Sillero-Zubiri C (eds): *Biology and Conservation of Wild Canids*. Oxford University Press, Oxford. 215–226.
- Kim BJ, Kim H, Won S, Kim HC, Chong ST, Klein TA, Kim KG, Seo HY, Chae JS (2014): Ticks collected from wild and domestic animals and natural habitats in the Republic of Korea. *The Korean Journal of Parasitology* 52, 281.
- Kowalczyk R, Jedrzejewska B, Zalewski A, Jedrzejewski W (2008): Facilitative interactions between the Eurasian badger (*Meles meles*), the red fox (*Vulpes vulpes*), and the invasive raccoon dog (*Nyctereutes procyonoides*) in Białowieża Primeval Forest, Poland. *Canadian Journal of Zoology* 86, 1389–1396.
- Lavrov NP (1971): The results of introductions of the raccoon dog (*Nyctereutes procyonoides*) in different provinces in the USSR (in Russian). *Trudy Kafedry Biologii Moskovskij Gosvdarstvennij Zaocnij Pedagogiceskij Institut* 29, 101–160.
- Lebeda M (1962): Findings of *Ixodes ricinus* in the deep layers of the skin and in the lymphatic ganglion (lymph

<https://doi.org/10.17221/38/2018-VETMED>

- node) of foxes (*Vulpes vulpes*). *Veterinarný Casopis Bratislava* 11, 193–205.
- Lee W, Lim J, Lee S, Lee I (1997): Redescription of *Haemaphysalis flava* and *Ixodes tanuki* collected from a raccoon dog in Korea. *The Korean Journal of Parasitology* 35, 1–8.
- Mulder JL (2013): The raccoon dog (*Nyctereutes procyonoides*) in the Netherlands – its present status and a risk assessment. *Lutra* 56, 23–43.
- Nakao M, Miyamoto K (1993): Isolation of spirochetes from Japanese ixodid ticks *Ixodes tanuki*, *Ixodes turdus*, and *Ixodes columnae*. *Japanese Journal of Sanitary Zoology* 44, 49–52.
- Nowak E (1973): Settlement and propagation of the raccoon dog (*Nyctereutes procyonoides* GRAY) in Europe (in German). *Beitrage zur Jagd- und Wildforschung* 8, 351–384.
- Nowak E (1984): Development of distribution and population of the raccoon-dog, *Nyctereutes procyonoides* (Gray, 1834) in Europe (in German). *Zeitschrift fuer Jagdwissenschaft* 30, 137–154.
- Nuttall GH (1914): Penetration of *Ixodes* beneath the skin. *Parasitology* 7, 258–259.
- Paulauskas A, Radzijeuskaja J, Rosef O (2012): Molecular detection and characterization of *Anaplasma phagocytophilum* strains. *Comparative Immunology, Microbiology and Infectious Diseases* 35, 187–195.
- Petko B, Stanko M (1991): Finding of the tick *Ixodes ricinus* under the skin of a fox in Slovakia. *Folia Veterinaria* 21, 159–162.
- Pitra C, Schwarz S, Fickel J (2010): Going west-invasion genetics of the alien raccoon dog *Nyctereutes procyonoides* in Europe. *European Journal of Wildlife Research* 56, 117–129.
- Portman RW, Dalke PD (1945): Infestation of a Red Fox by *Amylomma americanum*. *Journal of Economic Entomology* 38, 397.
- Siuda K (1993): Ticks (Acari: Ixodida) of Poland. Part II. Taxonomy and Distribution (in Polish). *Monografie Parazytologiczne* 12, PTW, Warsaw. 167–175.
- Smith DD, Frenkel JK, Smith EI (1986): Intradermal infestation of a red fox (*Vulpes vulpes*) by the lone star tick (*Amblyomma americanum*). *Journal of Wildlife Diseases* 22, 122–124.
- Tugwell P, Lancaster JL (1962): Results of a tick-host study in northwest Arkansas. *Journal of the Kansas Entomological Society* 35, 202–211.
- Wodecka B, Michalik J, Lane RS, Nowak-Chmura M, Wierzbicka A (2016): Differential associations of *Borrelia* species with European badgers (*Meles meles*) and raccoon dogs (*Nyctereutes procyonoides*) in western Poland. *Ticks and Tick-Borne Diseases* 7, 1010–1016.
- Yamauchi T, Agetsuma N, Araki N, Fukushima M (2012): Ixodid ticks collected from the raccoon dog *Nyctereutes procyonoides* albus and the common raccoon *Procyon lotor* in southern Hokkaido, Japan. *International Journal of Acarology* 38, 214–216.
- Zakrisson G (2010): Ticks, *Ixodes ricinus* in the subcutaneous tissues of a dog and foxes (in Swedish). *Svensk Veterinartidning* 15, 25–27.

Received: March 5, 2018

Accepted after corrections: October 8, 2018