

Bladder calculi and cystitis in Hanwoo steers without clinical symptoms: a case report

UI-HYUNG KIM*, KI-YONG CHUNG, SANG-RAE CHO, SUN-SIK JANG

National Institute of Animal Science, Pyeongchang-gun, Republic of Korea

*Corresponding author: uhkim@korea.kr

Citation: Kim UH, Chung KY, Cho SR, Jang SS (2019): Bladder calculi and cystitis in Hanwoo steers without clinical symptoms: a case report. *Veterinarni Medicina* 64, 33–36.

Abstract: Two Hanwoo steers were emergency-slaughtered due to symptoms of urethral obstruction. The steers were of the same age and were raised using the same feed management. The remaining 22 cattle in the finishing period showed no symptoms of urinary calculi until 30 months of age and were examined for the presence of bladder calculi when slaughtered. Bladder calculi were observed in 11 of 22 steers at slaughter (50%) and cystitis occurred in 13 of 22 steers (59.1%). There was a significant relationship between the presence of bladder calculi and the incidence of cystitis ($P < 0.05$).

Keywords: cattle; urinary calculi; nutrition; feeding management

Urinary calculi in beef cattle have long been regarded as an economic burden in the livestock industry (Kamiya et al. 2016). The risk factors for urinary calculi in cattle are diverse and complex; they can occur due to early castration, a highly concentrated diet, a high-phosphorous diet or improper calcium-phosphorous balance in feed rations, vitamin A deficiency, excessive oestrogen, hypervitaminosis D, reduced water intake and pastures containing silica or oxalate (Connell et al. 1959; Divers and Peek 2008; Pan et al. 2011; Kamiya et al. 2016). Hanwoo, a cattle breed native to Korea, has been raised to produce highly marbled beef to improve the income of farmers as well as meet consumer demand. Although an optimal diet for high-quality beef has been developed, the risk of urinary calculi still exists on Hanwoo steer farms. In previous studies, bladders of randomly slaughtered cattle were sampled to examine urinary calculi and cystitis (Herenda et al. 1990; Sardon et al. 2005; Yuk et al. 2005; Carvalho et al. 2006). In the present study, two emergency-slaughtered

Hanwoo steers that showed clinical symptoms of urethral obstruction were raised using the same feed management and were of the same age. The remaining 22 Hanwoo steers were examined during their finishing periods for the presence of bladder calculi when harvested at the slaughterhouse. Additionally, they were assessed for cystitis.

Case description

This study was conducted on a farm located in Daegwallyeong, Gangwondo, Republic of Korea. Twenty-four Hanwoo steers of the same age were raised using the same feed management. During the final fattening period, the veterinarian found and diagnosed abnormal symptoms in a 22-month-old Hanwoo steer. The steer exhibited symptoms such as tenesmus, tail twitching, colic and pain. These symptoms indicated urethral obstruction; thus, the steer was emergency-slaughtered. Two weeks after the emergency slaughter, the same symptoms oc-

Table 1. Bladder calculi and bladder tissue inflammation

Bladder calculi	No. of animals	No. of animals with bladder tissue inflammation	Percent
+	11	11	100 ^a
–	11	2	18.2 ^b

^{a,b} Different superscripts within the same column denote significant differences ($P < 0.05$) in Pearson's Chi-squared test with Yates's correction for continuity

curred in one of the remaining 23 cattle. When the steer was emergency-slaughtered in the slaughterhouse, the veterinarian confirmed the presence of calculi in the bladder and urethra. Bladder examination revealed calculi of varying sizes as well as haemorrhage in the mucosal membrane. Furthermore, one calculus was blocking the urethra. Although no clinical symptoms of urinary calculi were observed in the remaining 22 cattle, we hypothesised that bladder calculi were potentially present in the other cattle of the same age that were raised under the same feed management. We visited the slaughterhouse during the slaughter of the remaining 22 cattle and examined them for the presence of calculi. Various types, sizes and numbers of calculi were present in 11 of 22 Hanwoo steers (Table 1). The bladder mucosa was reddened and thickened (Figure 1). Bladder tissues were fixed in 10% neutral-buffered formalin and embedded in paraffin wax, and sections (3–5 μ m) stained with haematoxylin and eosin were examined histopathologically

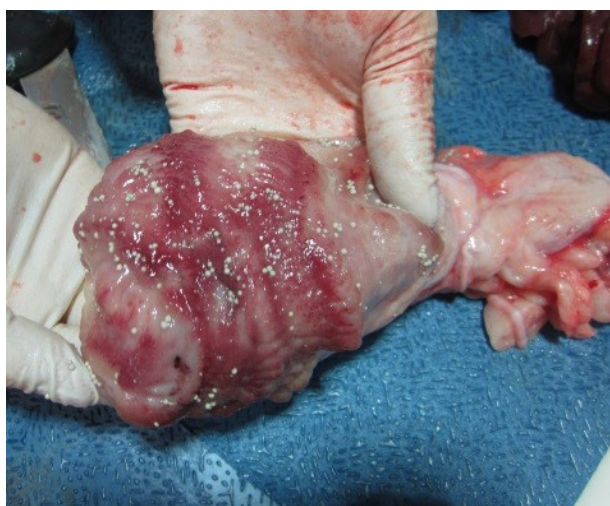

Figure 1. Bladder examination of the cattle that did not have clinical symptoms. A small round-shaped calculus was observed in the bladder, and the bladder mucosa was reddened and thickened

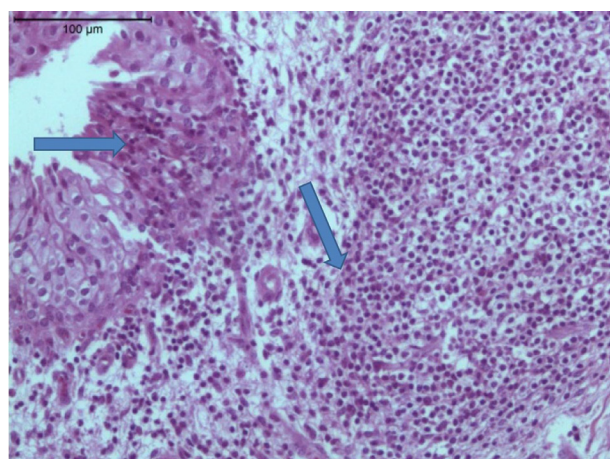


Figure 2. Histopathological examination of cystitis. Submucosal inflammation, lymphocytes and plasma cell infiltration (arrow) were observed

(Carvalho et al. 2006). Bladder submucosal oedema, transitional epithelial cell hyperplasia and submucosal inflammation characterised by lymphocytes and plasma cell infiltration were observed (Figure 2) in 13 of 22 bladders (Table 1). We used the FT-IR system 2000 (Perkin-Elmer Co., Waltham, USA) to analyse the chemical composition of urinary calculi. The calculus component analysis indicated that nine cattle had magnesium ammonium phosphate and carbonate apatite. The calculus components from the remaining two cattle were calcium oxalate monohydrate and uric acid (Table 2).

DISCUSSION AND CONCLUSIONS

In this study, the presence of bladder calculi was confirmed upon slaughter in 11 of 22 Hanwoo steers with no clinical signs of urinary calculi. In cattle, urolithiasis was not always obstructive. Connell et al. (1959) also reported that the urolithiasis in the majority of cattle failed to produce clinical manifestations and was only discovered upon post-mortem examination.

Table 2. Bladder calculi composition

No. of animals	Composition of bladder calculi	Percent
9	magnesium ammonium phosphate	80
	carbonate apatite	20
2	calcium oxalate monohydrate	50
	uric acid	50

<https://doi.org/10.17221/62/2018-VETMED>

Cho et al. (2005) suggested that urinary calculi, which may occur sporadically, depend on individual characteristics but may also be caused by common factors such as the environment in which the cattle are raised, breeding methods and diet. On this farm, calculi were present in 50% of steers of the same age, raised under the same feed management. Based on these results, the occurrence of urinary calculi in Hanwoo steers may be influenced by dietary and environmental factors rather than individual differences among the steers. Therefore, we assessed some elements of the farm's management.

The bladder calculi were analysed with regard to four major components: magnesium ammonium phosphate, carbonate apatite, calcium oxalate monohydrate and uric acid. Magnesium ammonium phosphate predominated among the tested components. This result is similar to a previous report that silica, magnesium ammonium phosphate, calcium carbonate and calcium oxalate are the most common types of crystals found in ruminants (Makhdoomi and Gazi 2013). This is also consistent with a previous report that calculi of the magnesium-phosphate type are commonly found in ruminant urolithiasis (Miranda et al. 2010; Kamiya et al. 2016). Miranda et al. (2010) reported that magnesium ammonium phosphate or calcium phosphate calculi often develop particularly in feedlots with fattened cattle that receive rations with high contents of cereal grains, oil meals, an excess of phosphorus and magnesium and relatively low levels of calcium and potassium. Hanwoo steers in this finishing period were raised and fattened in a barn throughout their lifetime. This management was similar to other feedlots with fattened cattle. The stock farmer chooses the level of concentrate and hay depending on the growth phase, i.e. growth feeding, early fattening or final fattening. The steers in this finishing period were fed a high-grain, fattening diet with unlimited feeding of rice straw. It is believed that this feeding method may have influenced the incidence of urinary calculi in the Hanwoo steers. Unfortunately, we did not conduct a component analysis of the calcium-to-phosphorus ratio in the feed.

On farms, in order to improve the marbling score of Hanwoo beef, bulls are typically castrated at seven months of age and raised until 30 months of age. Castration prior to sexual maturation may result in obstruction of the urethra due to poor development of urethral diameter (Wang et al. 1997;

Divers and Peek 2008; Pan et al. 2011). On this farm, no precautionary measures were taken to prevent urinary calculi, despite the increased risk of urethral obstruction by small calculi due to castration before sexual maturity. Two out of 24 steers were emergency-slaughtered. Tsuchiya and Sato (1988) reported that a diet that included ammonium chloride prevented the increase of urinary calculi. Therefore, it seems that measures should be taken on this farm to prevent the incidence of urinary calculi, such as the inclusion of ammonium chloride in steer diets. According to several studies, decreased water intake due to the freezing of water pipes or the supply of cold water in winter may have caused urinary calculi (Tsuchiya and Sato 1988; Divers and Peek 2008). However, in the present study, cattle water intake was not affected by such factors.

In this study, we confirmed mucosal lesions in the bladders of Hanwoo steers and analysed the relationship between the occurrence of bladder calculi and cystitis. Although differences in the degree of cystitis were observed, all 11 cattle with bladder calculi had cystitis. These results indicated a significant relationship between the presence of bladder calculi and the incidence of cystitis.

Connell et al. (1959) reported that the presence of bladder calculi can produce lesions by irritating the bladder wall. Herenda et al. (1990) reported that a positive relationship between bladder calculi and cystitis was found in 5% of all slaughtered animals (994 specimens). Cho et al. (2005) reported that in long-term fattening of Hanwoo cattle, the cattle with calculi had a higher incidence of mucosal congestion in the bladder than cattle without calculi. However, in our study, the association between bladder calculi and cystitis was stronger than observed in other studies. In addition, Yuk et al. (2005) reported that bladder calculi can mechanically damage bladder mucosa and were highly correlated with bleeding, congestion, hyperplasia and pyuria. The authors also reported an association between the presence of bladder calculi and the incidence of bladder inflammation.

We confirmed that the Hanwoo steers in the present study were castrated before sexual maturity and fattened by overfeeding on a high-grain diet. However, ammonium chloride was not administered to prevent urinary calculi. Of the 24 steers that were of the same age and were raised using the same feed management, two steers were slaugh-

tered due to symptomatic calculi. In the slaughterhouse, 11 additional cattle showed bladder calculi. The results of this study confirmed that the incidence of calculi may be affected by feed management. Additionally, there was a possibility of further damage to the farm if feed management practices were left unchecked. If urinary calculi occur in a herd of cattle it is necessary to examine the conditions under which the cattle are raised together until the time of slaughter. This may prevent further health problems such as emergency death caused by calculi.

Until now, few studies have reported the incidence of calculi after examining all the cattle in one group. In this study, the cattle from the group were of the same age and were subject to the same feed management. After two steers in the group were emergency-slaughtered due to symptoms of urethral obstruction, we visited the slaughterhouse during the slaughter of the remaining steers and inspected them for the presence of calculi. Although no clinical symptoms of urinary calculi were observed in the remaining steers, the incidence of bladder calculi was 50%. According to these results, the occurrence of urinary calculi in Hanwoo steers may be influenced by dietary and environmental factors rather than by individual differences among the steers. Based on examination of all of the steers' bladder membranes and bladder calculi, we also confirmed a significant relationship between the presence of bladder calculi and the incidence of cystitis.

REFERENCES

- Carvalho T, Pinto C, Peleteiro MC (2006): Urinary bladder lesions in bovine enzootic haematuria. *Journal of Comparative Pathology* 134, 336–346.
- Cho YI, Hur TY, Kang SJ, Suh GH, Ko MS, Kim KH, Na KJ, Kim IH (2005): The survey of urinary calculi following long feeding period in Korean native steers. *The Korean Society of Veterinary Clinics* 22, 357–364.
- Connell R, Whiting F, Forman SA (1959): Silica urolithiasis in beef cattle: I. Observation on its occurrence. *Canadian Journal of Comparative Medicine* 23, 41–46.
- Divers TJ, Peek SF (2008): *Rebhun's Diseases of Dairy Cattle*. 2nd edn. Elsevier Saunders. 462–464.
- Herenda D, Dukes TW, Feltmate TE (1990): An abattoir survey of urinary bladder lesions in cattle. *The Canadian Veterinary Journal* 31, 515–518.
- Kamiya Y, Kamiya M, Hattori I, Hayashi Y, Funaba M, Matsui T (2016): Effect of feeding sweet-potato condensed distillers solubles on intake and urinary excretion of minerals in Japanese Black steers. *Animal Science Journal* 88, 79–85.
- Makhdoomi DM, Gazi MA (2013): Obstructive urolithiasis in ruminants – A review. *Veterinary World* 6, 233–238.
- Miranda M, Rigueira L, Suárez ML, Carbajales P, Moure P, Fidalgo LE, Failde D, Vazquez S (2010): Xanthine nephrolithiasis in a Galician blond beef calf. *Journal of Veterinary Medical Science* 72, 921–923.
- Pan XL, Wen ZS, Zou XT, Zhou EK, Kou HQ, Xu ZR, Zhang WJ (2011): Chemical composition and microstructure of uroliths associated with the feeding of high-level cottonseed meal diet to sheep. *Research in Veterinary Science* 91, 405–411.
- Sardon D, de la Fuente I, Calonge E, Perez-Alenza MD, Castaño M, Dunner S, Peña L (2005): H-ras immunohistochemical expression and molecular analysis of urinary bladder lesions in grazing adult cattle exposed to bracken fern. *Journal of Comparative Pathology* 132, 195–201.
- Tsuchiya R, Sato M (1988): Incidence and countermeasure of urolithiasis in fattening cattle. *Journal of the Japan Veterinary Medical Association* 41, 36–39.
- Wang X, Huang K, Gao J, Shen X, Lin C, Zhang G (1997): Chemical composition and microstructure of uroliths and urinary sediment crystals associated with the feeding of high-level cottonseed meal diet to water buffalo calves. *Research in Veterinary Science* 62, 275–280.
- Yuk HS, Lee OH, Rim BR (2005): Abattoir survey of bladder lesions in Korean cattle. *The Korean Journal of Veterinary Service* 28, 31–38.

Received: April 6, 2018

Accepted after corrections: October 8, 2018