

## Gas-filled urachal abscess with a pinging sound in a heifer calf

REIICHIRO SATO\*, KAZUTAKA YAMADA, YASUNORI SHINOZUKA, HIDEHARU OCHIAI, KEN ONDA

*Faculty of Veterinary Sciences, University of Azabu, Chuo-ku, Sagamihara, Kanagawa, Japan*

*\*Corresponding author: r-sato@azabu-u.ac.jp*

**Citation:** Sato R, Yamada K, Shinozuka Y, Ochiai H, Onda K (2019): Gas-filled urachal abscess with a pinging sound in a heifer calf. *Veterinari Medicina* 64, 362–366.

**Abstract:** A 6-month-old crossbred of a Holstein and Japanese Black heifer calf weighing 95 kg presented with a history of intermittent abdominal distension and failure to thrive. The physical examination identified a pinging sound over the dorsal left flank. The abdominal radiography showed a huge gas-filled mass. The intravenous urography revealed no communication between the mass and the urinary bladder. Although the visual examination and palpation of the umbilicus did not reveal visible abnormalities, an umbilical disease was suspected because the animal exhibited poor growth, depression, and a hunched back posture. When the eschar adhering to the centre of the umbilicus was removed, the presence of a fistulous tract was revealed. The umbilical ultrasound examination revealed an intra-abdominal abscess and the fistulography demonstrated that the abscess communicated with the umbilicus. The abscess, compressing into the rumen, was observed by computed tomography. From these images, it was diagnosed as an umbilical cord remnant abscess and a definitive diagnosis of a urachal abscess was obtained by open abdominal surgery and the subsequent removal of the mass. The calf was discharged from the university hospital on day 14 after the operation. This case shows that a urachal abscess should be considered when a pinging sound is present, even if the animal exhibits no swelling or pain of the umbilicus.

**Keywords:** cattle; computed tomography (CT); fistulography; intravenous urography

The most commonly infected umbilical remnant is the urachus. Dysuria, pollakiuria, pyuria, and cystitis are all sequelae of urachal abscesses in calves. The size and shape of the mass and the presence of drainage (Smith 1985) are important considerations while making a diagnosis. Additionally, palpation of the umbilicus area, assessment of the body temperature, and pain induction should also be taken into account. However, in this report, the calf had no visible external umbilical infectious signs, but had a large urachal abscess inside the abdominal cavity with a left dorsal pinging sound on auscultation.

### Case description

A 6-month-old crossbred Holstein and Japanese Black heifer calf, weighing 95 kg, had intermittent abdominal distension. The animal was housed in a free-stall barn and reared in the same fashion as the other age-matched calves. The animal exhibited poor growth, coarse hair coat, depression, and a hunched back posture. A visual examination and palpation did not reveal swelling or pain of the umbilicus. On percussion over the dorsal left flank, a pinging sound was heard on auscultation.

<https://doi.org/10.17221/61/2019-VETMED>

The referring veterinarian suspected a possible left abomasum displacement and performed open abdominal surgery. After opening the right flank, he found an enlarged gas-filled mass extending from the pelvic cavity to the rumen, highly adherent to the left abdominal wall and difficult to detach. The referring veterinarian, thus, suspected an enlarged bladder and judged it difficult to treat in the field. Therefore, the calf was admitted to Azabu University Veterinary Teaching Hospital for further diagnosis and treatment.

At the time of admission, the calf exhibited poor growth, had coarse hair coat, depression, and slight dehydration. In addition, the left flank was distended and, on percussion over the dorsal left flank, a pinging sound was heard on auscultation.

The calf's white blood cell count ( $14.5 \times 10^9/l$ ; reference range:  $4.9\text{--}12.0 \times 10^9/l$ ) was increased. The serum total protein (74 g/l; reference range: 67–74 g/l) and fibrinogen (17.6  $\mu\text{mol/l}$ ; reference range: 5.9–20  $\mu\text{mol/l}$ ) concentrations were high but within the standard range. The serum Albumin-Globulin ratio (0.4) was decreased. The bacterial culture of the aseptically collected urine did not isolate any significant bacteria, and a urine dipstick test (Lovesticks™, Siemens Healthcare Japan Co., Ltd., Tokyo, Japan) gave normal results.

An abdominal radiography (KXO-80S/40, Toshiba, Tokyo, Japan) showed a gas-filled intra-abdominal mass. An intravenous urography was then performed (Iohexol, Omnipaque; Daiichi-Sankyo, Co., Ltd., Tokyo, Japan) with the calf in the standing

position to exclude the urinary system disease. On intravenous urography, the urinary bladder was enhanced, but the gas-filled mass with fluid was not, demonstrating that there was no communication between the urinary bladder and the mass (Figure 1). Although the visual examination and palpation of the umbilicus did not reveal swelling, pain, or purulent drainage, an umbilical disease was suspected, because the animal exhibited poor growth, depression, and a hunched back posture. A small eschar adhering to the centre of the umbilicus was revealed and when removed a fistulous tract was found.

An umbilical ultrasound scan using a 7.0-MHz linear probe (MyLab One VET, Esaote, Maastricht, Netherlands) revealed a dorsocaudal intra-abdominal abscess. A feeding catheter (TOP Corp., Tokyo, Japan) was inserted into the fistula, and a fistulography was performed (Iohexol, Omnipaque) in the standing position. Contrast accumulated in the ventral portion of the mass (Figure 2) and dispersed within the mass when the calf was recumbent, demonstrating that the mass communicated with the umbilicus and was most likely an umbilical abscess.

The animal was then restrained in the prone position under general anaesthesia, and an abdominal computed tomography (CT; BrightSpeed16, GE Healthcare, Port Washington, NY, U.S.A.) was performed to assess the intra-abdominal conditions before the operation. A huge mass containing gas and fluid, adjacent to the urinary bladder and compressing the rumen, was identified (Figure 3).

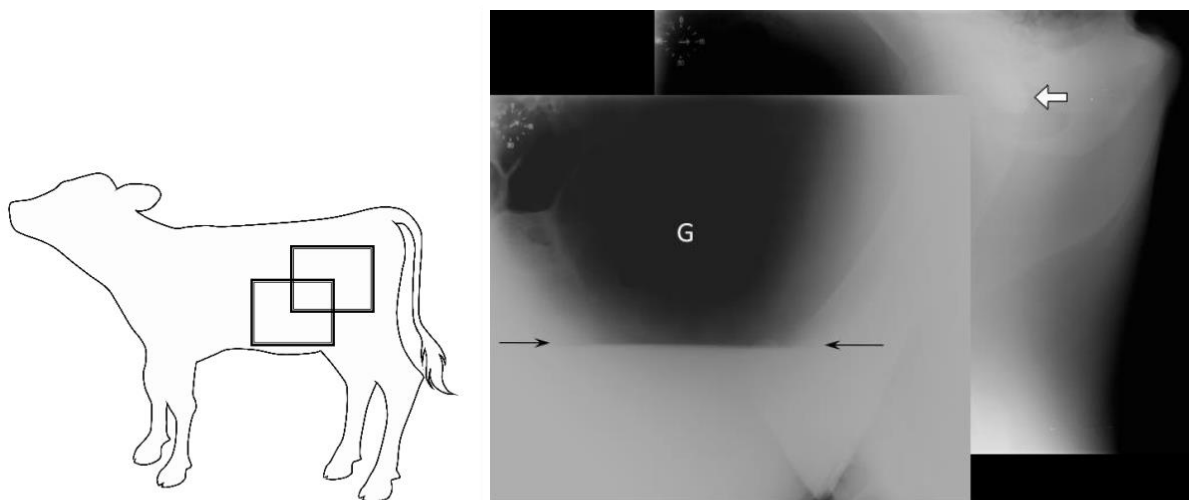


Figure 1. The intravenous urography images with the calf in the standing position

The black arrows indicate the fluid line identified in the lumen of the mass (G) when the fluid was not enhanced. The open arrow indicates the urinary bladder with the contrast agent

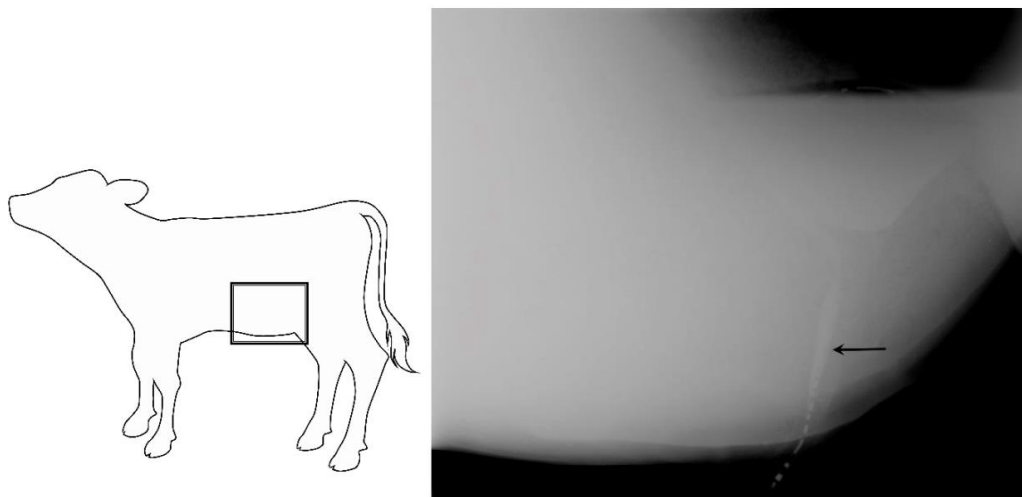


Figure 2. Fistulography performed in the standing position

The fistulography with contrast, injected through a catheter placed into the umbilicus, demonstrating that the mass was connected to the umbilicus (arrow)

From these images, the mass was diagnosed as a urachal abscess.

Abdominal surgery was performed to remove the mass from the abdominal cavity. The calf was fasted for 24 h prior to surgery, and intramuscular cefazolin sodium was administered (5 mg/kg) (Cefazolin-Chu; Fujita Pharmaceutical, Tokyo, Japan) to prevent a perioperative infection. The calf was guided to a recumbent position before general anaesthesia was administered. The calf was anaesthetised by continuous administration of isoflurane (Isoflu; Zoetis Japan, Tokyo, Japan) during the operation. Local anaesthesia at the left

flank and umbilical area was administered subcutaneously with procaine hydrochloride (Kyoritsu Seiyaku Corporation, Tokyo, Japan). Preoperatively, the umbilical opening was closed with purse-string sutures. A 15-centimetre long incision was made on the skin of the left flank, and the abdomen was exposed. The mass was extensively adhering to the left abdominal wall and was difficult to excise. The adhesions of the mass were peeled off carefully, and the intra-abdominal cavity was examined. The adherence of the mass to the abdominal walls was confirmed; moreover, the mass invaginated the rumen and adhered to the bladder in the pel-

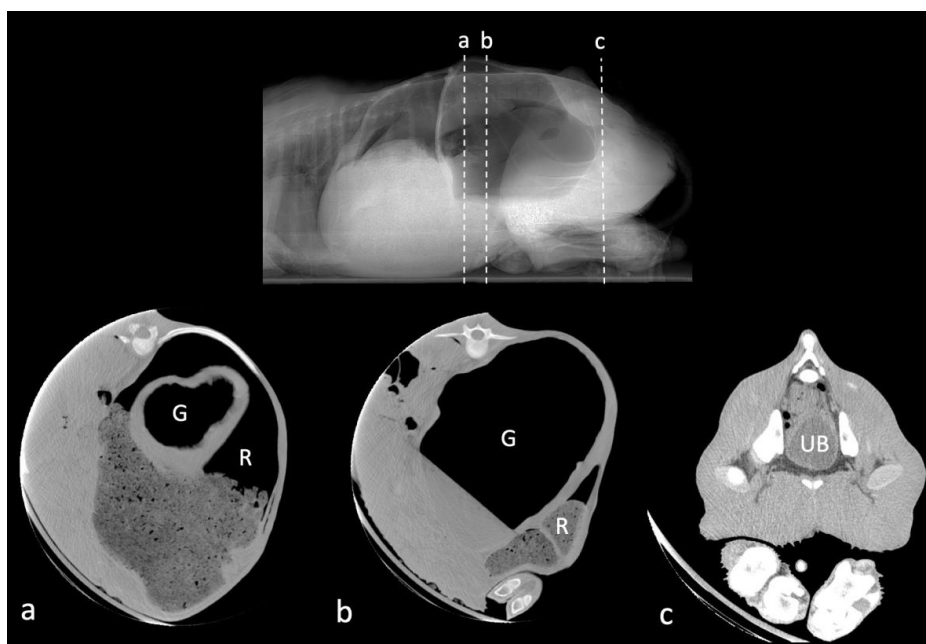


Figure 3. The transverse computed tomographic images at different levels of the abdomen

The heart-shaped structure with a lumen was identified as the rumen (R), and a fluid line was noted in the mass (G). The urinary bladder was identified in the caudal abdomen (UB)

B = urinary bladder; G = gas; R = rumen

<https://doi.org/10.17221/61/2019-VETMED>

vic cavity. The site of the attachment of the mass and the bladder was coagulated and enucleated with a vessel-sealing device (Ligasure Maryland 44; Medtronic plc, Dublin, Ireland). Furthermore, the other adhesions were carefully peeled off.

The abdomen was further exposed; a fusiform-shaped incision was made on the skin, around the umbilical area, and after separating the umbilical region and subcutaneous tissue, a sterile surgical glove was placed over the umbilical region. Using a nylon suture (USP-3), the exposed umbilical cord and the sterile glove were sutured to prevent leakage from the umbilical opening. After creating a circular incision on the umbilical stump, the mass was excised from the abdominal cavity. The mass measured 37 × 31 × 2 cm and appeared to be a single abscess, containing approximately 1.5 kg of purulent material (Figures 4A and 4B).

*Trueperella pyogenes*, *Pasteurella multocida*, and *Fusobacterium necrophorum* were isolated from the mass and the material taken from the umbilicus. Drug sensitivity testing (BD Sensi-Disc, Becton Dickinson Japan, Tokyo, Japan) showed that all the bacteria were sensitive to ampicillin, cefazolin, and enrofloxacin, and that *T. pyogenes* was sensitive to penicillin.

Procaine penicillin G (5000 IU/kg BW) (Kyoritsu Seiyaku Inc., Tokyo, Japan) was administered *i.m.* for ten days after surgery. The calf was discharged from the university hospital on day 14 after the operation. The written informed consent was obtained from the owner for publication of this case report and the accompanying images.

## DISCUSSION AND CONCLUSIONS

The umbilical cord consists of a single umbilical vein, paired umbilical arteries, and the urachus. The urachus connects the foetal bladder to the allantoic sac. In ruminants, the urachus retracts into the abdomen and atrophies shortly after birth. Normally, the umbilicus becomes thin and dries out 3 to 4 days after delivery (Rings 1995).

In calves, diseases of the urachus are usually associated with omphalitis. If the urachal cord remnants remain untreated, an ascending infection can lead to a urachal abscess, cystitis, or suppurative nephritis. Typical clinical signs include abdominal pain, standing with an arched back, or poor performance. Additionally, a dribbling of purulent discharge from the umbilical fistula, pollakiuria, and dysuria maybe present, especially in a urachal infection (Lischer et al. 1994; Kasari and Roussel 1999; Baxter 2004).

The history, the clinical symptoms, and a physical examination are useful in making an accurate diagnosis. Deep abdominal palpation should be performed with the calf in a lateral or dorsal recumbent position (Bouckaert and deMoor 1965; Smith 1985; Baird 2008), and a more accurate diagnosis can be obtained using an ultrasound scan (Hassel et al. 1995; Staller et al. 1995; Braun et al. 2006). However, cases of intraperitoneal infection have no visible umbilical swelling (Diefenderfer and Brightling 1983; Dean and Robertson 1988), and diagnosis can be difficult (House et al. 2015). Therefore, it is necessary to carefully palpate the umbilicus for the presence of increased sensitivity around the navel.

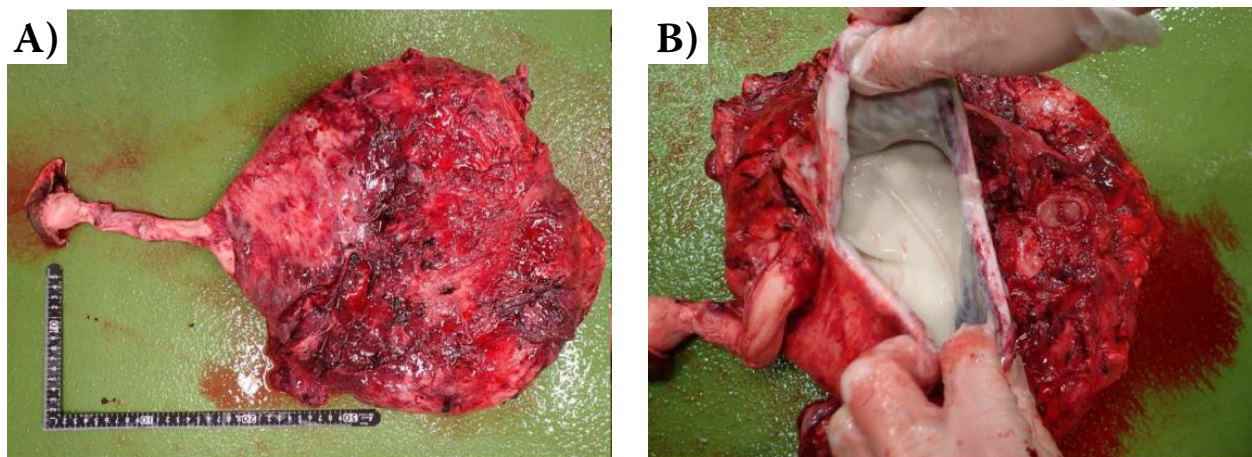


Figure 4. The surgical specimen obtained after resection of the urachal mass. (A) The resected urachal abscess measured 37 × 31 × 25 cm. (B) The mass internally appeared to be a single large abscess and contained approximately 1.5 kg of purulent material

<https://doi.org/10.17221/61/2019-VETMED>

At first, the referring veterinarian suspected an abomasum disease and performed open abdominal surgery because of a pinging sound heard from the left flank. But he touched a large gas-containing mass near the cavity of the pelvis. When a pinging sound is auscultated from the left flank, its origin can be suspected to be the rumen, or the peritoneum, or a left displaced abomasum (LDA). In the case of ruminal tympany, the pinging sound is heard from the whole left paralumbar fossa, and can extend dorsally to the spinal column, while in the case of LDA, it is heard from the left paralumbar fossa to the eleventh rib (Terra and Reynolds 2015).

In general, when a pinging sound is heard from the left flank, a urachal abscess is rarely suspected. In this case, although no abnormality in the umbilical region was identified, an umbilical disease was suspected due to the poor growth and the hunched back posture, and subsequently a large gas-filled abscess was demonstrated by ultrasound examination.

After surgery, the resected mass was confirmed to be a urachal abscess. Although there are numerous reports of urachal abscesses in cattle (Smart et al. 1978; Diefenderfer and Brightling 1983; Trent and Smith 1984; Starost 2001), to the best of our knowledge, there are no reports of this phenomenon being associated with a pinging sound over the abdominal cavity in a 6-month-old calf. The presence of such a ping in a calf exhibiting no swelling or pain of the umbilicus suggests the possibility of an umbilical cord remnant disorder, including a urachal abscess.

## Acknowledgement

We thank to the staff and student assistants at Azabu University for caring for the heifer during hospitalization.

## REFERENCES

- Baird AN (2008): Umbilical surgery in calves. *Veterinary Clinics: Food Animal Practice* 24, 467–477.
- Baxter GM (2004): Calf surgery. In: Fubini SL, Ducharme NG (eds): *Farm Animal Surgery*. 1<sup>st</sup> edn. Saunders Elsevier, St. Louis. 477–484 p.
- Bouckaert JH, deMoor A (1965): Surgical treatment of umbilical infections in calves. *The Veterinary Record* 3, 771–774.
- Braun U, Nuss K, Wapf P, Lischer C (2006): Clinical and ultrasonographic findings in five cows with a ruptured urachal remnant. *The Veterinary Record* 159, 780–782.
- Diefenderfer DL, Brightling P. (1983): Dysuria due to urachal abscessation in calves diagnosed by contrast urography. *The Canadian Veterinary Journal* 24, 218–221.
- Dean PW, Robertson JT (1988): Urachal remnant as a cause of pollakiuria and dysuria in a filly. *Journal of the American Veterinary Medical Association* 192, 375–376.
- Hassel DM, Tyler JW, Tucker RL, Sondhof AF (1995): Clinical vignette: urachal abscess and cystitis in a calf. *Journal of Veterinary Internal Medicine* 9, 286–288.
- House JK, Gunn AA, Chuck G, McGuirk SM (2015): Initial management and clinical investigation of neonatal disease. In: Smith BP (ed): *Large Animal Internal Medicine*. 5<sup>th</sup> edn. Elsevier Mosby, St. Louis. 286–301 p.
- Kasari TR, Roussel Jr. AJ (1999): Neonatal disease and disease management. In: Howard JL, Robert AS (eds): *Current Veterinary Therapy Food Animal Practice*. 4<sup>th</sup> edn. Saunders Elsevier, Philadelphia. 62–65 p.
- Lischer CJ, Iselin U, Steiner A (1994): Ultrasonographic diagnosis of urachal cyst in three calves. *Journal of the American Veterinary Medical Association* 204, 1801–1804.
- Rings DM (1995): Umbilical hernias, umbilical abscesses, and urachal fistulas. *Surgical considerations. Veterinary Clinics Food Animal Practice* 11, 137–148.
- Terra RL, Reynolds JP (2015): Ruminant history, physical examination, welfare assessment, and records. In: Smith BP (ed.): *Large Animal Internal Medicine*. 5<sup>th</sup> edn. Elsevier Mosby, St. Louis. 5–6 p.
- Smart ME, Ferguson JG, Vaillancourt D (1978): Sequela to a urachal abscess in a Hereford heifer. *Veterinary Medicine, Small Animal Clinician* 73, 1557–1558.
- Smith DF (1985): Clinical assessment and surgical management of umbilical masses in calves. *Bovine Practitioner* 20, 82–84.
- Staller GS, Tulleners EP, Reef VB, Spencer PA (1995): Concordance of ultrasonographic and physical findings in cattle with an umbilical mass or suspected to have infection of the umbilical cord remnants: 32 cases (1987–1989). *Journal of the American Veterinary Medical Association* 206, 77–82.
- Starost MF (2001): *Haemophilus somnus* isolated from a urachal abscess in a calf. *Veterinary Pathology* 38, 547–548.
- Trent AM, Smith DF (1984): Pollakiuria due to urachal abscesses in two heifers. *Journal of the American Veterinary Medical Association* 184, 984–986.

Received: May 17, 2019

Accepted after corrections: July 16, 2019